The Right Atrium (RA)

بستقبل الدم من

- Receives blood from: (1) Superior vena cava, (2) Inferior vena cava, (3) Coronary sinus.

بفصل بين right atrium و left atrium

هي منطقة دائرية فيها جوة بس مسكرة

(بالجنين) لما كانت فاتحة اسمها

- Interatrial septum has fossa ovalis (remnant of foramen ovale)
- Blood passes through the right atrioventricular orifice (which's guarded by the tricuspid valve) into right ventricle

3

بوابة بين right atrium and right ventricle

The Right Ventricle (RV)

بستقبل الدم من right atrium عشان يضخه باتجاه lungs عشان يصير oxygenated

- Possess trabeculae carneae – raised bundles of cardiac muscle fiber.

زي طعجات بتعطينا contraction أقوى

- Cusps of the tricuspid valve are connected to chordae tendinae which are connected to papillary muscles (3 in number).

الخيوط اللي بتربط بين cusps and Papillary muscles

عددهم 3

- Interventricular septum.
- Blood leaves through pulmonary orifice which's guarded by the pulmonary semilunar valve into pulmonary trunk.

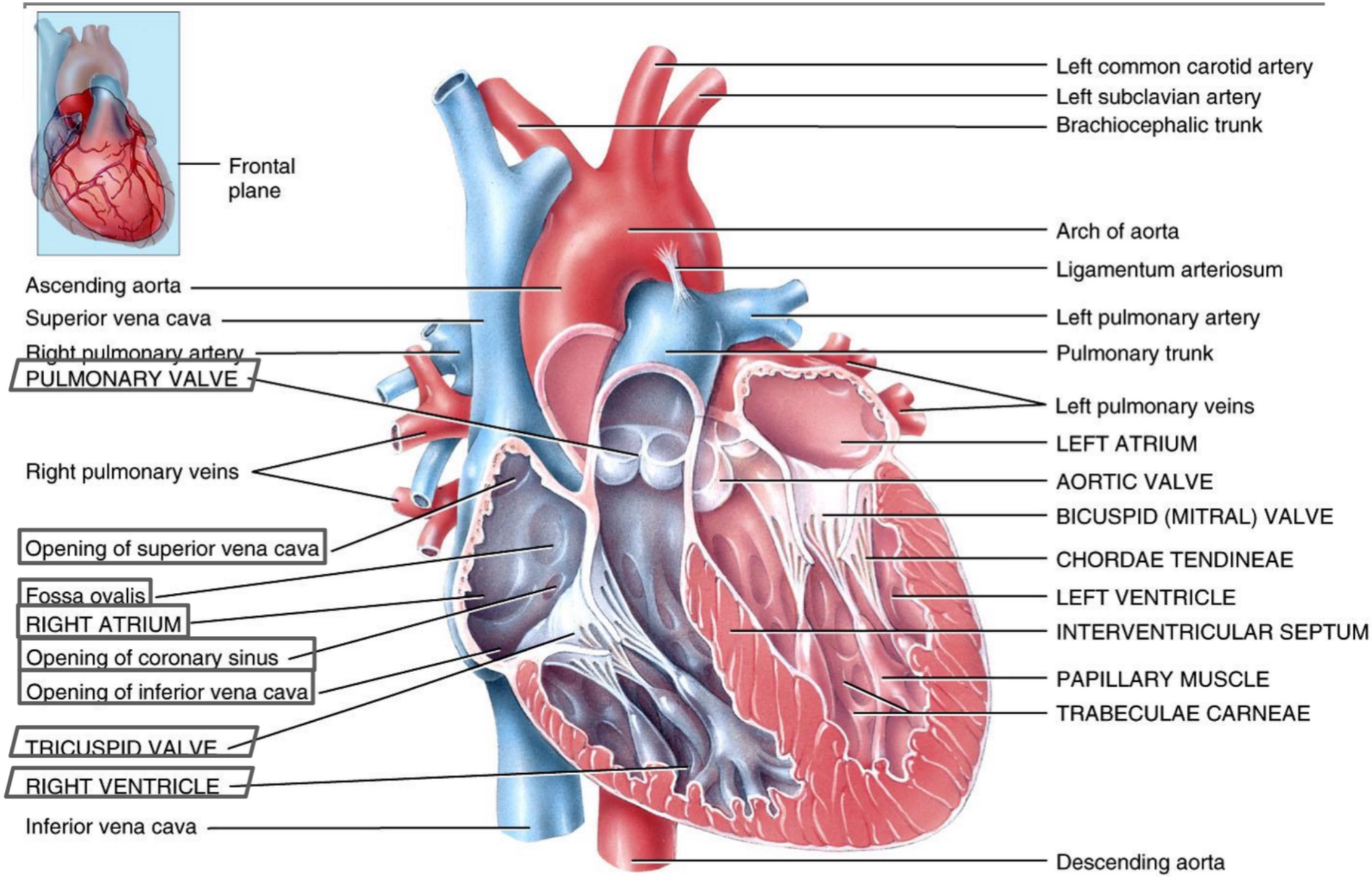

(a) Anterior view of frontal section showing internal anatomy

Fig.17: The left atrium and ventricle of the heart.

بستقبل الدم من lungs عن طريق Pulmonary veine

The Left Atrium (LA)

- About the same thickness as right atrium.
- Receives blood from the lungs through pulmonary veins.
- Blood Passes through the left atrioventricular orifice into the left ventricle. This orifice is guarded by the bicuspid/ mitral valve.

البوابة بين left atrium and left ventricle

2

اسم تاني

The Left Ventricle (LV)

لأنه هو بضخ الدم للجسم كله

- Thickest chamber of the heart.
- The cusps of the mitral valve are attached to chordae tendinae which are attached to papillary muscles (2 in number).

عددهم 2

- Blood passes through aortic orifice into the aorta. This orifice is guarded by the aortic semilunar valve.
- The interventricular septum is convex on the side of the RV making the cavity of the LV larger. مقعر

يعني شوي ماخذ من مساحة Right ventricle فمساحته أكبر

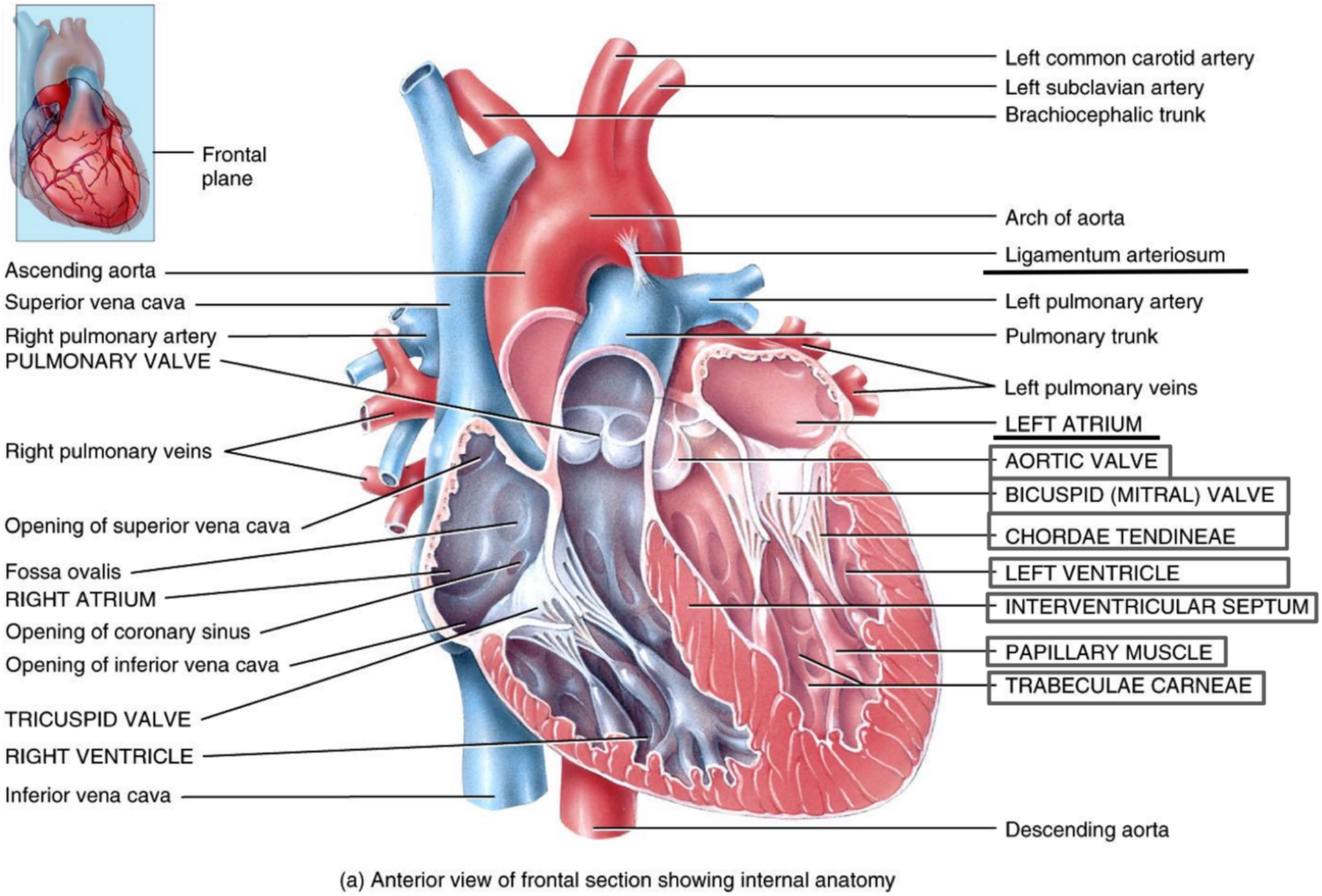

(a) Anterior view of frontal section showing internal anatomy

Fig.19: The right atrium and ventricle of the heart.

The Fibrous Skeleton of the heart

مكون من

- Dense collagenous connective tissue that forms (1) base for the valves, (2) point of insertion for cardiac muscles and (3) electrical insulator between atria and ventricles.

Functions:

كلهم بجبتوا بال Fibrous skeleton

عازل

Values كل كلهم

الـ base تبعهم هو Fibrous skeleton

* AV node هو المكان الوحيد اللي بين Atriumm و ventricle ما فيه Fibrous skeleton

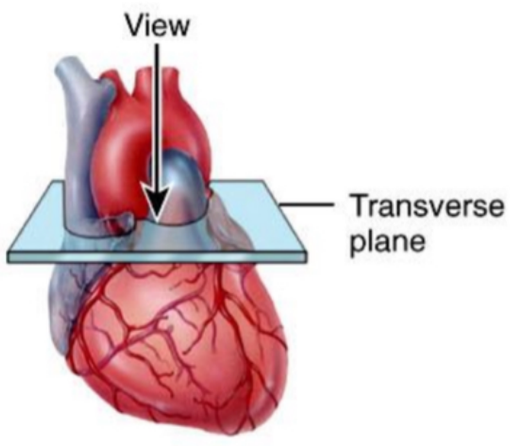

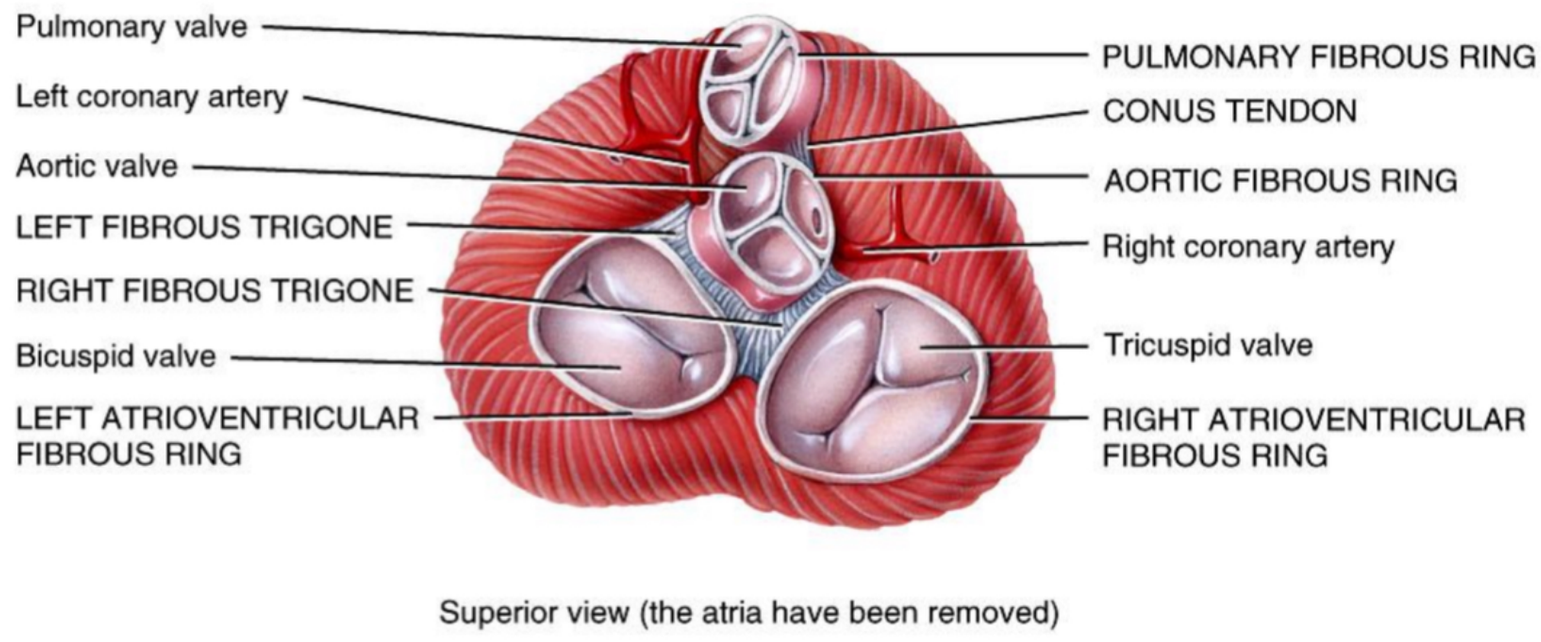

Fig.20: The shape and position of the fibrous skeleton of the heart.

Valves: Atrioventricular Valves

Artery → أي اشي بطلع من heart

Veine → أي اشي برجع لل heart

- Tricuspid (3 cusps) and bicuspid (2 cusps)

  بين right atrium and right ventricle

  بين left atrium and left ventricle

1. Atria contract/ ventricles relaxed
   - The higher pressure inside the atria pushes the cusps aside opening the valves and the cusps project into the ventricles

     رح يفتحوا من بعض
   - In the ventricles, papillary muscles are relaxed and chordae tendinae slack مش شادين
2. Atria relax/ ventricles contract
   - Higher pressure in the ventricles drives the cusps towards the atria until edges of the cusps meet and close the valve
   - Papillary muscles بتشد contract tightening the chordae tendinae and preventing regurgitation

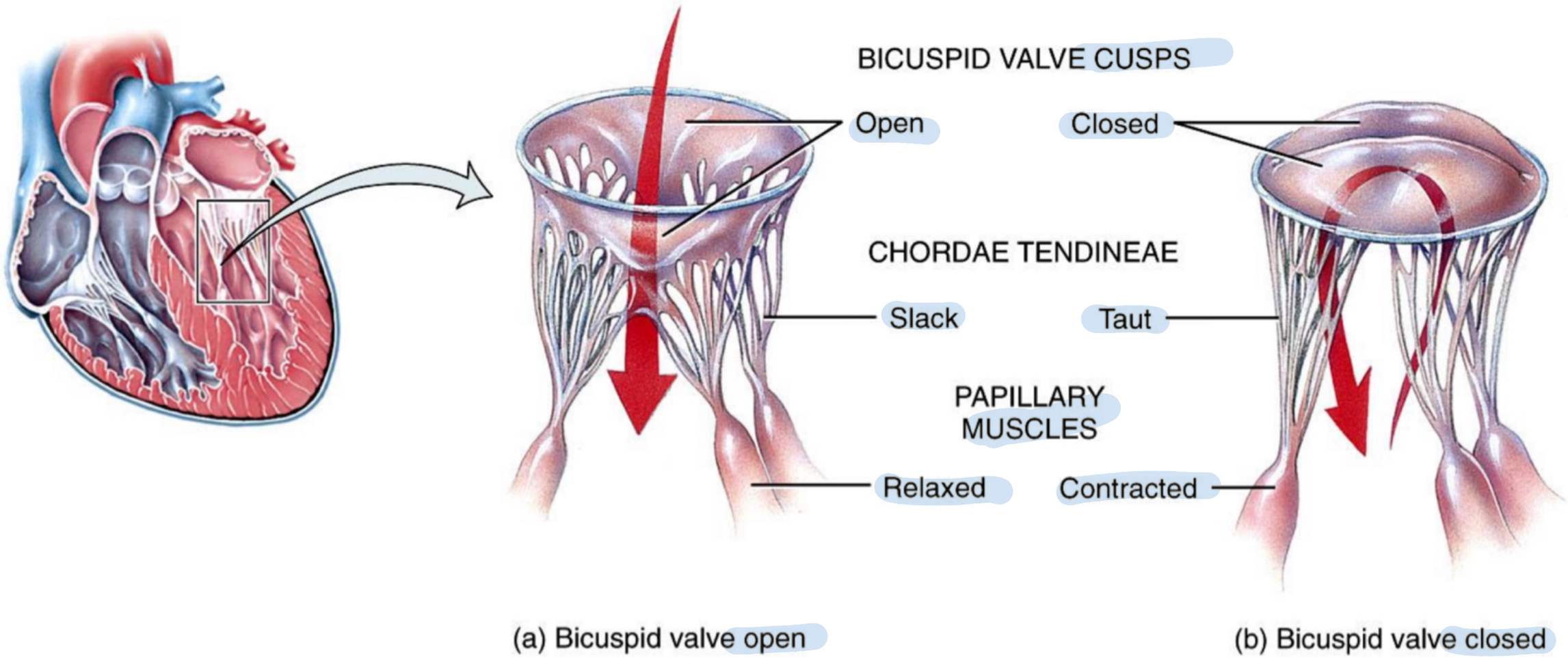

Fig.21: How the atrioventricular valves function.

Valves: Semilunar Valves

بين right ventricle و Pulmonary trunk (Pulmonaric)

بين left ventricle و Aorta (Aortic)

- Aortic and pulmonary valves (each has 3 cusps).
- When ventricles contract, the pressure in ventricles exceeds pressure in arteries pushing the cusps aside and opening the valve.
- As ventricles relax, some blood flows back towards the ventricles, but blood fills the valve cusps closing them tightly. → نتيجة الجاذبية gravity
- The aortic valve has openings for the coronary arteries into which blood flows when LV relaxes.

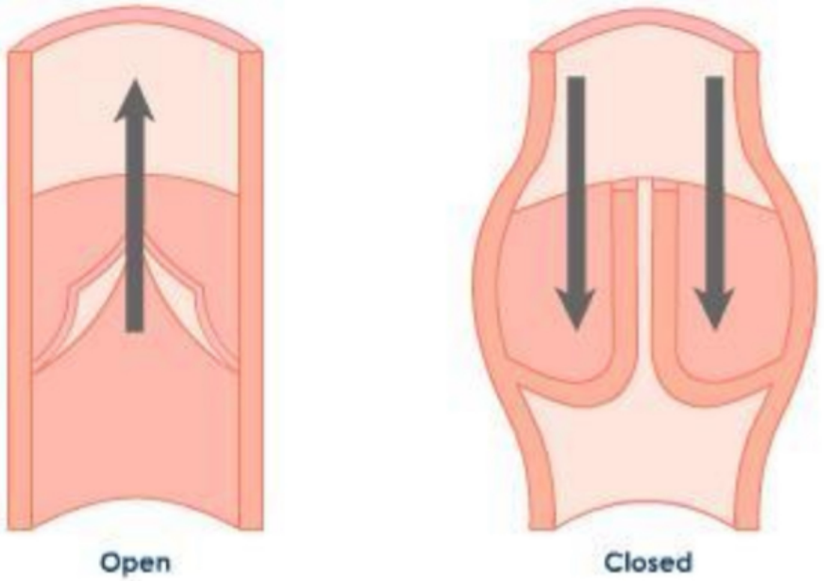

The Coronary Circulation

* كبار السن و الناس الرياضيين عندهم تفرعات أكثر من الشباب

← فالجلطة عند كبار السن مش قاتلة

← لكن عند الشباب قاتلة

- The heart has its own network of blood vessels.
- Coronary arteries branch from ascending aorta.

حكينا بتطلع من الخرقة اللي بال Aortic semilunar valve

- Anastomoses provide collateral circuits

تفرعات

- Allows heart muscle to receive sufficient oxygen even if an artery is partially blocked

وبمجرد ما طلع رح يطلع شريانين

- **Left Coronary Artery** → Anterior Interventricular and Circumflex branches

بطلع منه تفرعين

- **Right Coronary Artery** → Marginal and Posterior Interventricular branches

تفرعين

- Coronary veins:
  - Include the **Great, Anterior, and Middle cardiac veins**
  - Drain into **Coronary Sinus** (in the coronary sulcus)

نجيبوا الدم الـ deoxygenated باتجاه الـ heart (على Coronary sinus)

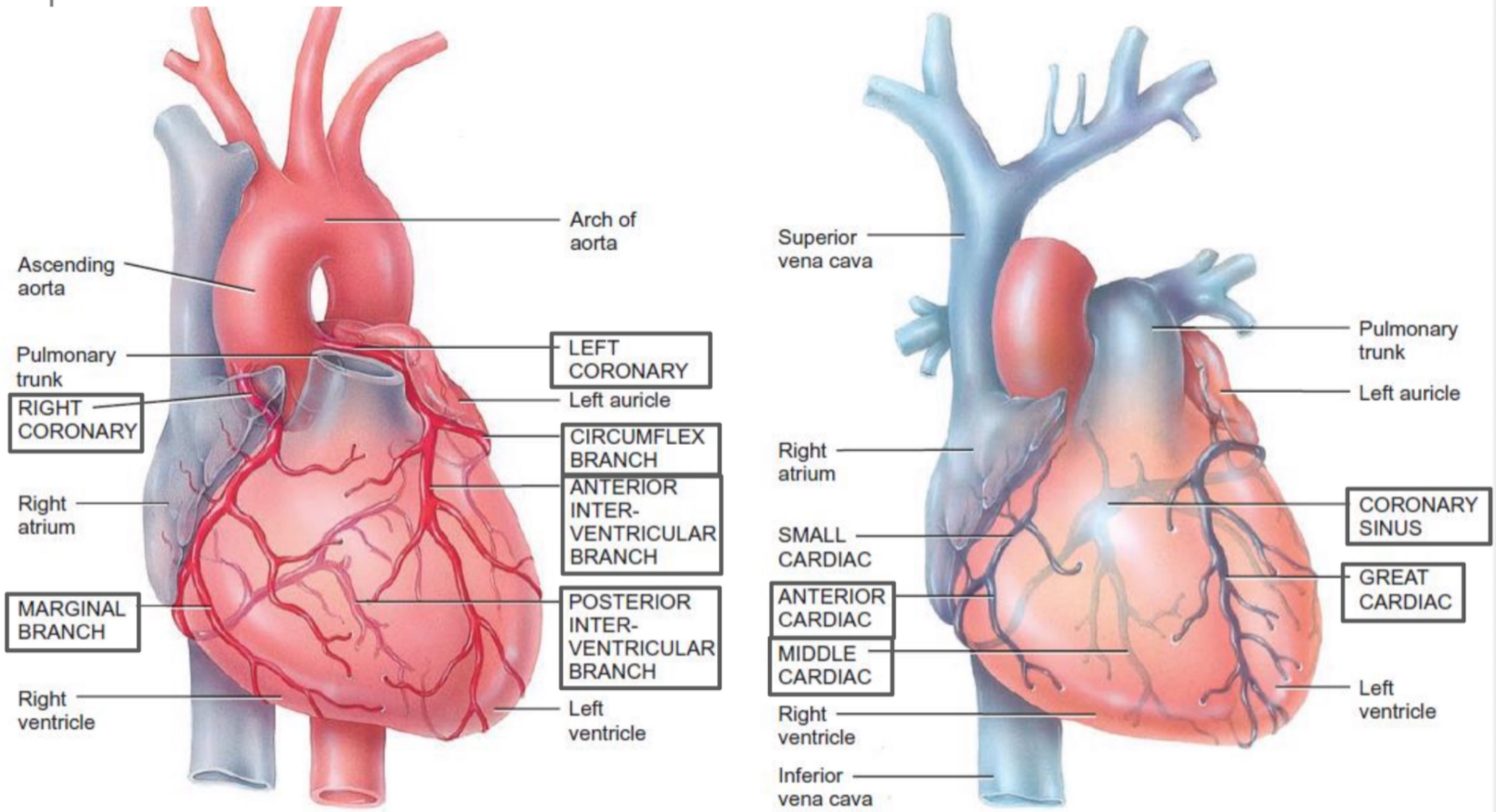

Fig.24: The coronary circulation.

The Blood Vessels

- Tube-like structures through which blood is carried

- 5 main types:
  - **Arteries** – carry blood AWAY from the heart
  - **Arterioles**
  - **Capillaries** – site of exchange
  - **Venules**
  - **Veins** – carry blood TOWARDS the heart and they possess valves

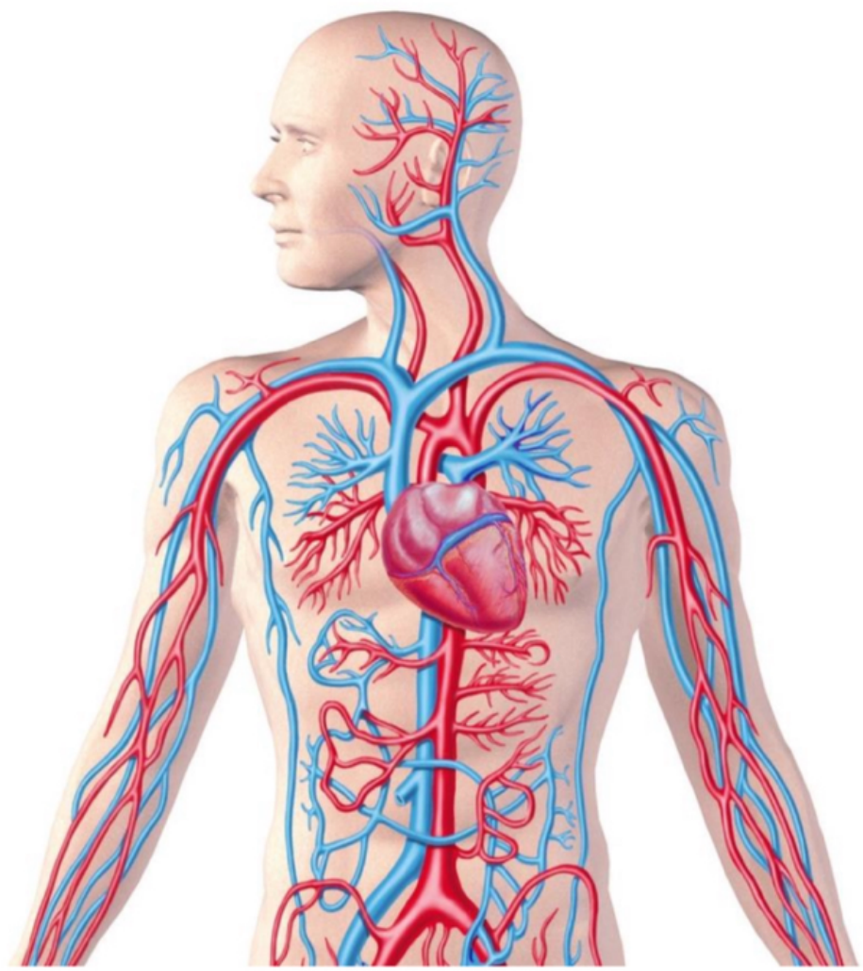

Fig.25: The blood vessels.

Aorta → Big arteries → small arteries → Arterioles → Capillaries → Venules → small Veins → Big Veins → Inferior and superior Vena cava

Pulmonary and Systemic Circulations
Two circuits in series

- **Pulmonary circulation**
  - RA receives deoxygenated blood from systemic circulation
  - RA pumps blood into RV
  - RV ejects blood into pulmonary trunk then pulmonary arteries
  - Gas exchange in pulmonary capillaries in the lungs
  - Pulmonary veins take blood to LA
- **Systemic circulation**

  بوزع الدم على الجسم كامل
  - LA receives oxygenated blood from lungs
  - LA pumps blood into LV
  - LV ejects blood into aorta
  - Systemic arteries, arterioles
  - Gas and nutrient exchange in systemic capillaries
  - Systemic venules and veins lead back to RA

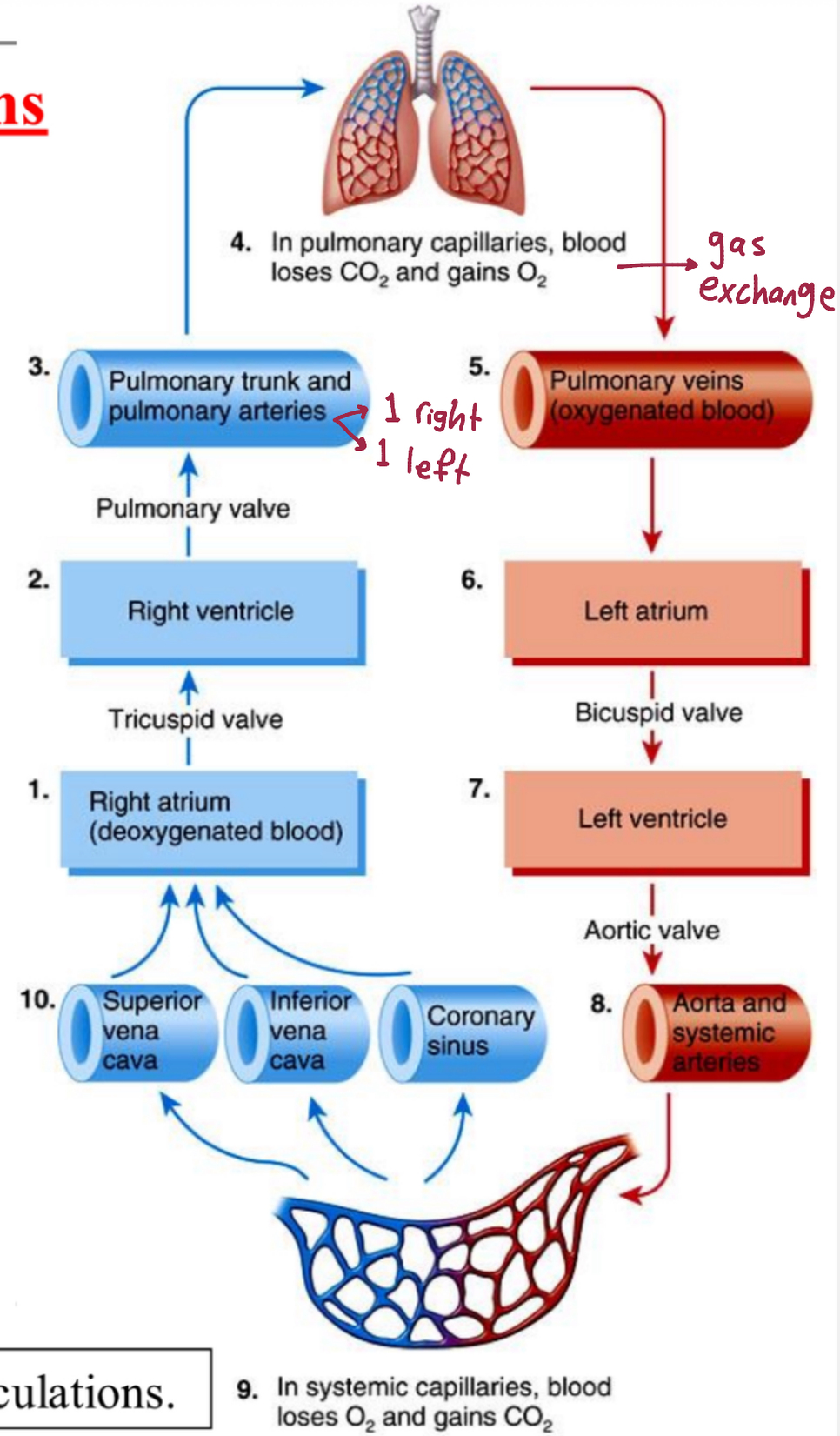

Fig.27: The two circulations.

Major Blood Vessels of the Thorax

The Major Arteries

The Aorta أكبر شريان موجود بالجسم

- ❖ Is the largest artery in the body
- ❖ Arises from the LV

- ❖ Divided into 4 parts:

1. Ascending aorta
2. Arch of aorta قوس
3. Descending Thoracic aorta
4. Abdominal aorta

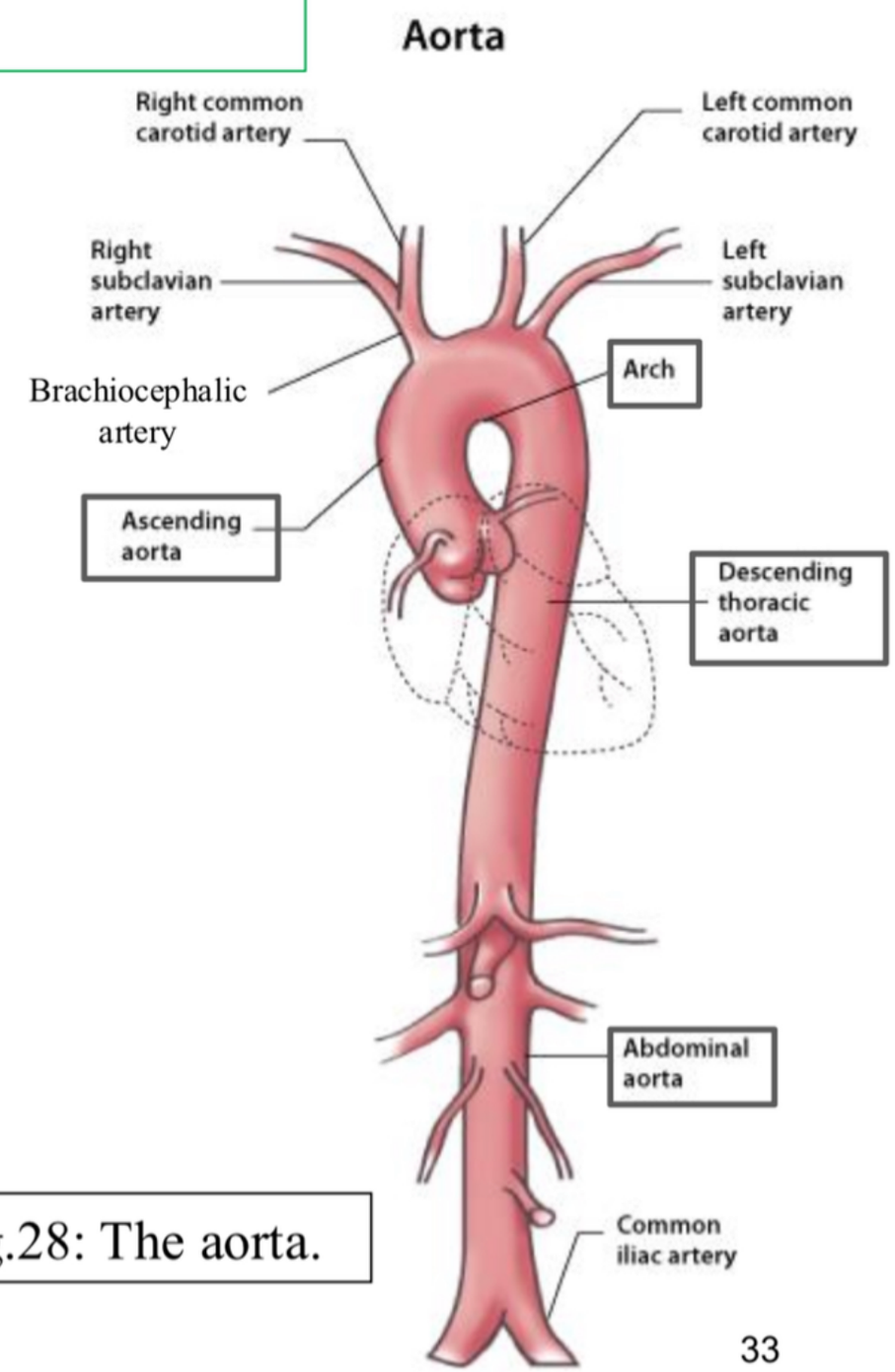

Fig.28: The aorta.

Important Branches (In the Thorax):

- Ascending Aorta:

1. Right Coronary artery
2. Left Coronary artery

- Arch of aorta:

1. Brachiocephalic trunk
   a. Right Subclavian artery
   b. Right Common Carotid artery
2. Left Common Carotid Artery
3. Left Subclavian Artery

- Descending Thoracic Aorta:

Gives various branches to nearby structures

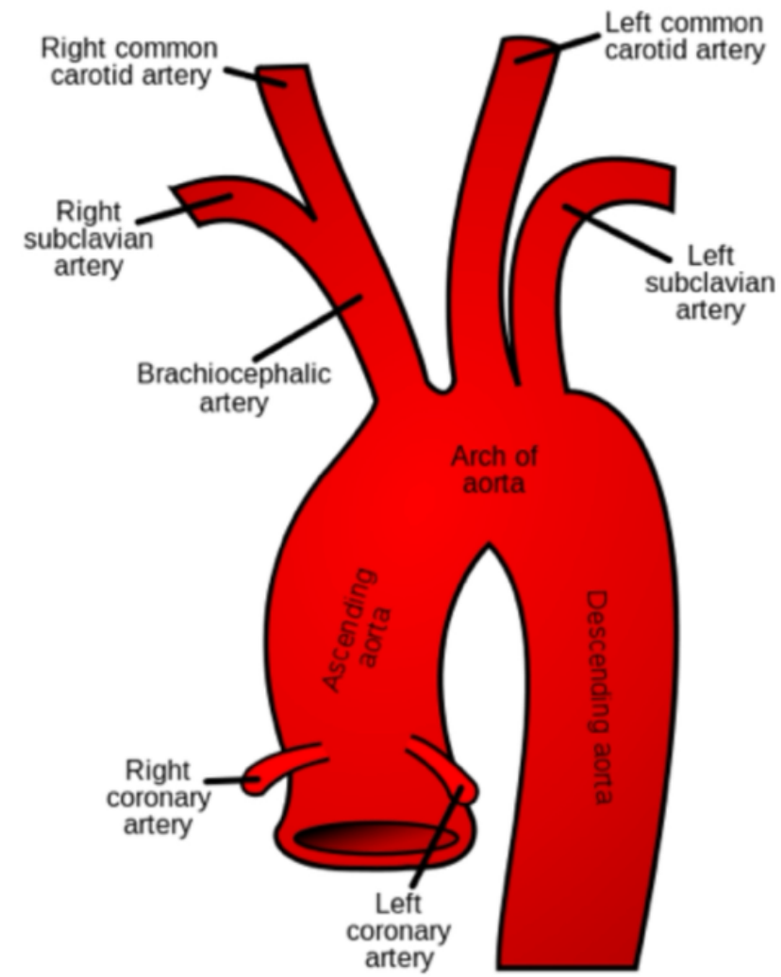

Fig.29: The ascending and the arch of aorta.

The Pulmonary Trunk

deoxygenated blood هو الوحيد اللي بحمل

- Is the only artery in the body which carries ***deoxygenated blood.***
- Arises from the RV. Right ventricle بطلع من
- Divides into the Right and Left Pulmonary arteries which pass into the corresponding lung. بروح على right lung — بروح على left lung
- The pulmonary trunk is connected to the arch of aorta by the *ligamentum arteriosum*. → بين Pulmonary trunk و arch of aorta

لما كان الطفل جنين ببطن امه كانت عبارة عن قناة duct

  - This is the remnant of the ductus arteriosus which shunted blood from the pulmonary trunk to the aorta during fetal life thus bypassing the lung. During fetal life, the fetus does not need his lungs because it already receives oxygenated blood from the mother.

أهمية القناة ← الطفل لما كان جنين عم بختلط الدم الموجود بال Pulmonary trunk مع الدم الموجود بال Aorta

(ما بختلط دم oxygenated مع deoxygenated لانه هو اصلاً ما رح يروح عالـ lungs , رح يصير تبادل

بينه و بين الأم ، و لكن لما ينولد الطفل الـ lungs شغالة و رح بختلط الدم oxygenated و deoxygenated)

تجيب ال Blood من :

- Subclavian vein
- external jugular vein
- Internal jugular vein

بتجمعوا مع بعض Brachiocepholic vein وبعطونا

right (superior vena cava اقرب ل → Vertical)

left (superior vena cava بمشي مسافة حتى يوصل → Horizontal)

The Brachiocephalic veins:

The right brachiocephalic vein is vertical (عامودي), whereas the left is more horizontal (افقي). They drain blood from the head, neck and upper limbs. They unite to form the Superior Vena Cava (SVC) which opens into the RA.

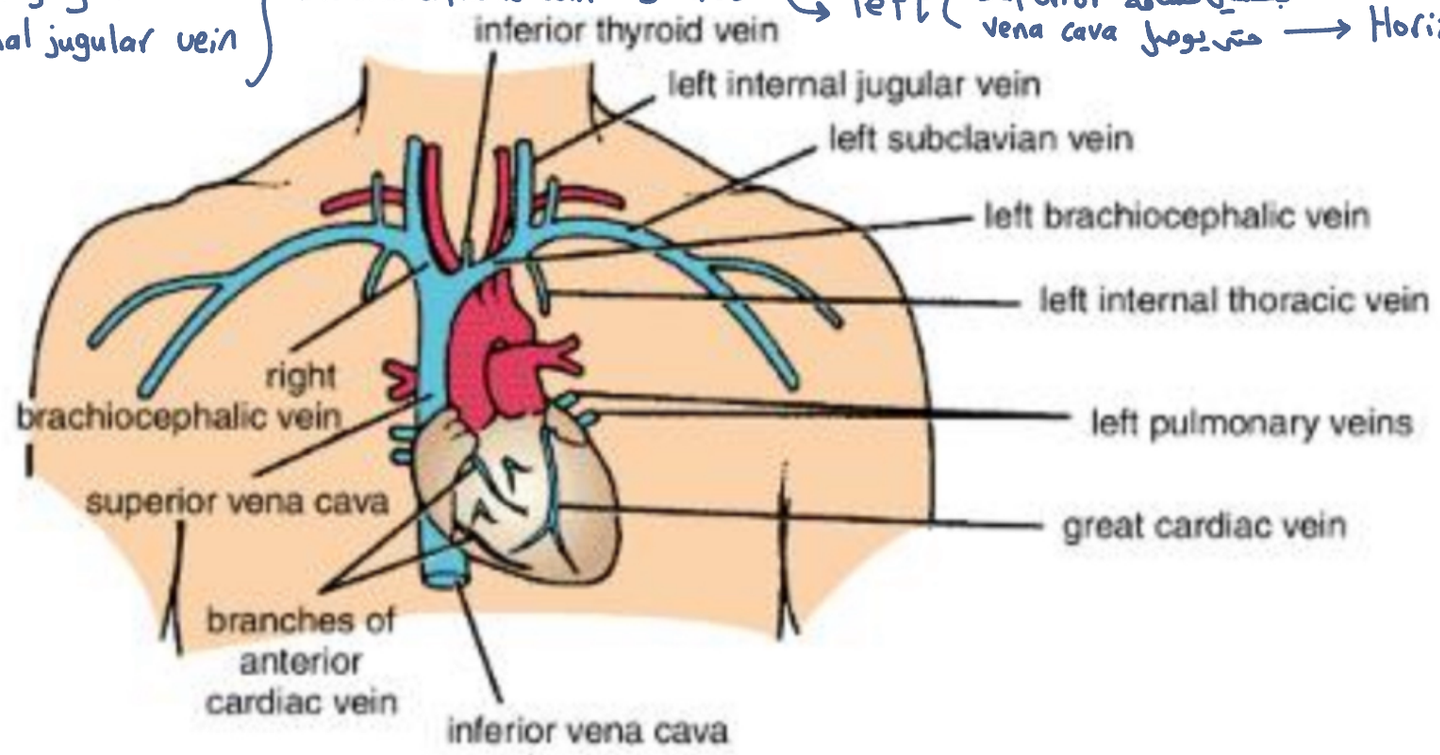

Fig.32: The major veins of the thorax..

The Pulmonary Veins:

2 from left

2 from right

These are 4 veins (2 from each lung) that carry ***oxygenated blood*** from the lung to the LA of the heart. Only veins that carry oxygenated blood.

The Inferior Vena Cava (IVC):

lower limb and Abdomin من deoxygenated blood تجيب كل

This is formed in the abdomen and its terminal part enters the thorax (through the diaphragm) to open into the RA.

تركيبيز

- الـascending aorta فيها فتحتين واحد بطلع منه right coronary artery وواحد بطلع منه left coronary artery
الـleft بطلع منه واحد descending وواحد circumflex , والـright بطلع منه واحد marginal وواحد posterior
هلا هاي وهي طالعة ، حكينا وين الفتحات تاعتها ؟...فوق الـaortic semilunar valve حكينا هاي الخزقة اول ما تسكر
الـsemilunar valve رح تفتح عشان تطلع الدم باتجاه coronary arteries

- بعدين رح نيجي على القوس الـarch واللي هو بطلع منه ٣ تفرعات ، تفرع اسمه left common carotid و left
subclavian artery و brachiocephalic artery
- الـbrachiocephalic بطلع منه تفرعين واحد اسمه right common carotid والتاني right subclavian ، فمعناها في عنا
subclavian 2 و common carotid 2, الـleft بطلع مباشرة من الـaorta و الـright بطلعو من brachiocephalic اللي
طالعة من الـaorta
- هلا الـsubclavian بتغذي منطقة upper limbs و الـcommon carotid بغذي neck , head , face , brain يعني كلشي
بالمنطقة هاي
- هلا بحكيلنا common carotid سواء كانت right or left بضل طالع ascending بضل اسمه common carotid artery
وشو بكون بموازاته يعني اشي قريب عليه ؟ vagus nerve وinternal jegular vein (ما حكينا common jegular حكينا
internal) هلا بضل طالع common carotid لفوق لانه هو بالنهاية artery بالتالي هو بحمل blood away from the
heart ف رح يضل طالع لفووق لحد ما يوصل لعند جزء من larynx الحنجرة اسمه thyroid cartilage ، بهاي المنطقة
الـcommon carotid بعطينا فرعين ، فرع اسمه internal carotid artery وفرع external carotid artery
المكان اللي بتفرع فيه الـcommon carotid الى internal and external هو المكان اللي رح نحس فيه pulse

- هلا من اسمه external carotid artery فشو رح يغذي ..رح يغذي كلشي برا الـskull , الـinternal رح يغذي كلشي داخل
skull مثل brain, ف رح يدخل internal carotid باتجاه الـskull باتجاهالـbrain

- هلا لما يتفرع common carotid الي external and internal حكينا internal بدخل skull فمين بكون بموازاته ..
الـinternal jegular اللي كان بموازاة الـcommon carotid فلما تفرع لـexternal and internal الـinternal jegular
بضل بموازاة internal carotid. المهم نعرف هون انه internal carotid بدخل للداخل

- بالendocrine system حكينا الpituitary بتكون قاعدة علىhypophyseal fossa تبعت sphenoid bone واللي بغذيها اشي اسمه superior hypophyseal artery و inferior hypophyseal artery واللي هي عبارة عن branches من الinternal carotid artery internal carotid لانه هو بغذي كلشي داخل skull فبالتالي من تفرعاته كلشي موجود داخل skull او داخل brain رح يغذيهم تفرعات الinternal carotid, كونلنا circle of willis وغذالنا الbrain
اما external carotid غذى كلشي برا skull

- هلا بدنا نرجع بالعكس كveins
كل الاجزاء الموجودة داخل الskull رح يتجمع الدم الdeoxygenated جوا sinuses اللي همه عبارة عن جيوب تجاويف enlarged veins بتجمع فيها الدم ، مجموعة الsinuses رح تجمع الدم الdeoxygenated وتحطها بالinternal jugular vein اللي حكينا انه كان ماشي parallel with the common carotid وكمل parallel with internal carotid artery ، هسا العكس بده يطلع على شكل internal jugular وبكون على سواه الinternal فبصير artery, هلا الinternal jugular رح يجمع الدم deoxygenated منsinuses ورح يغادر الskull ،رح يغادر skull من فتحات موجودة داخل skull اسمها jugular foramen

- الexternal jugular ما اله اي علاقة بالinternal بعيييد ، هلا الinternal jugular طلع من skull فرح يجيب كل الدم الdeoxygenated من منطقة face and neck ، بالمقابل كان external carotid هو اللي بغذيها كartery ، بس الinternal jugular بجيب الدم deoxygenated من هاي الاماكن وبضل نازل كinternal jugular لحد ما يصير على سوى thyroid cartilage, على سوى thyroid cartilage انا بعرف انه هاد المكان بتفرغ فيه common carotid الى internal and external, هلا المفروض انه لازم يكون عندي internal and external jugular بس ما عندي هاد الاشي (ما بتحدوا مع بعض)، المهم الinternal jugular بضل نازل لتحت للما يوصل subclavian vein ، طيب ما في عنا external jugular ؟ امبلا في بس الexternal jugular بجيب الدم الdeoxygenated من منطقة الneck بس ما بلتقي مع internal jugular ، كل واحد من مكان مفصول

- اللي بصير انه subclavian vein هو اللي بجيب الدم deoxygenated من منطقة upper limbs بضل ماشي بجيه external jugular ،ما التقى مع الinternal jugular جابلي الدم الdeoxygenated منneck بيجي external jugular بمشي شوي وبيجي internal jugular بكمل as brachiocephalic vein اللي حكينا left وright بدخلوا على superior vena cava

Major Blood Vessels of the Head and Neck

The Major Arteries

The Carotid Arteries

- Responsible for supplying blood to structures in the head and neck.
- They ascend superiorly in the neck where they are closely related to the internal jugular vein and the vagus nerve.
- About the level of the upper border of the thyroid cartilage, each artery divides into the ***external and internal carotid arteries.*** (this is where the carotid pulse can be felt).

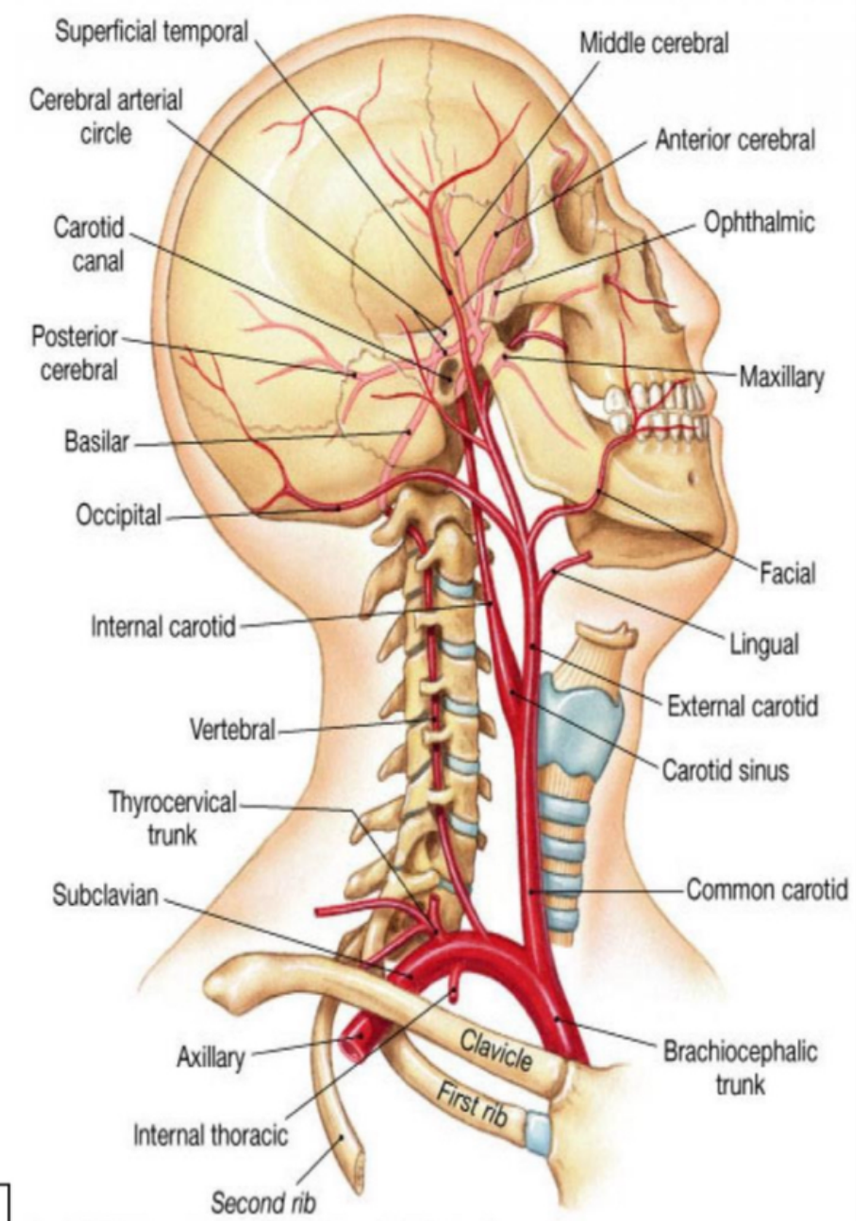

Fig.33: The carotid arteries.

The Subclavian Arteries

- The right and left subclavian arteries arch laterally from their origins.
- At the outer border of the first rib they become the axillary artery.
- The scalenus anterior muscle is related to this artery.
- They give off several branches that supply various structure in the head, the neck, and even the chest

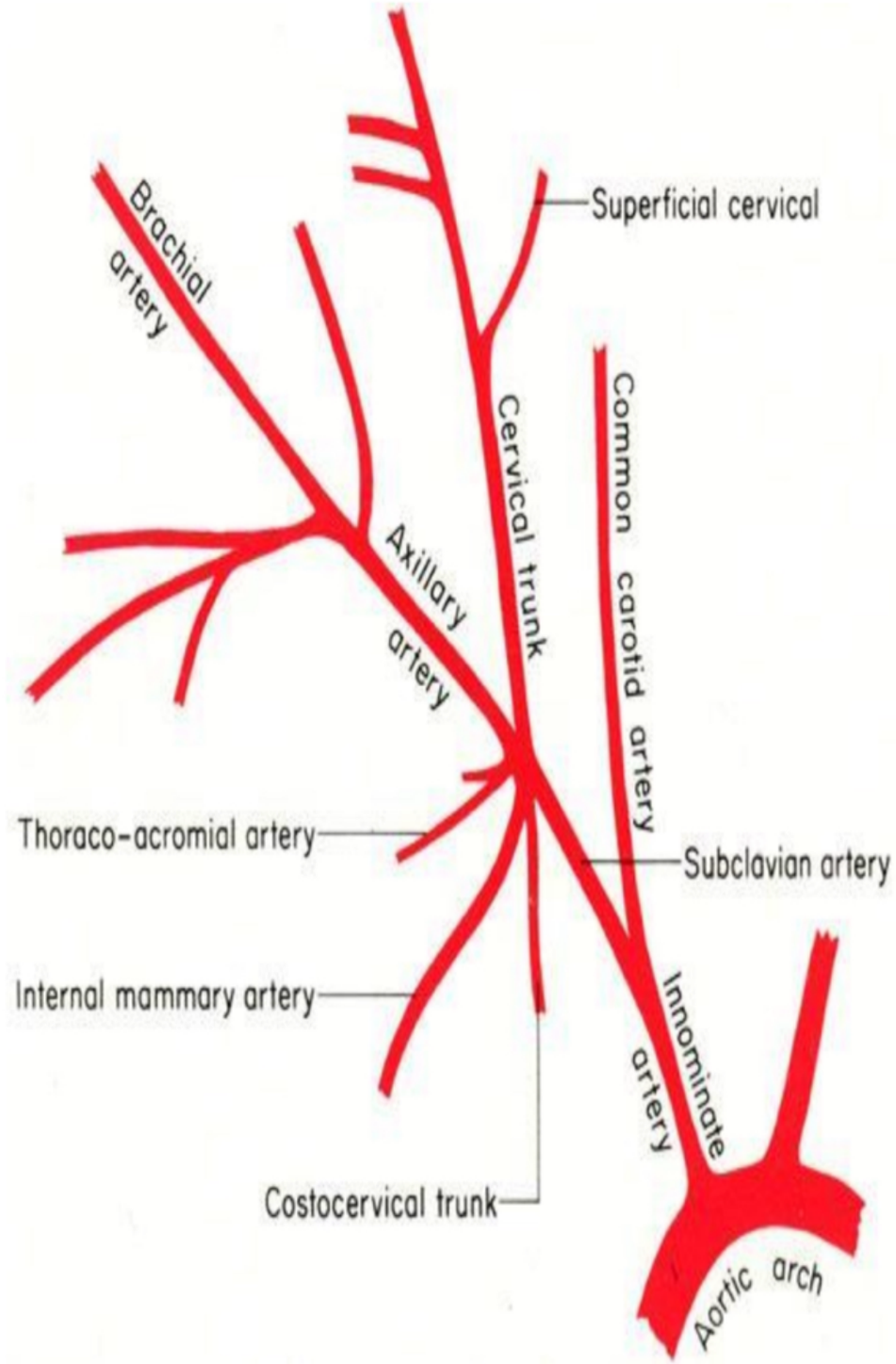

Fig.35: The subclavian arteries.

The Major Veins

- All blood from the brain (and related structures) drains into ***sinuses*** (enlarged veins). These sinuses eventually drain into the **internal jugular vein** (IJV).
- The IJV is formed inside the skull, leaves the skull by passing through the jugular foramen and descends through the neck in close relation to the internal carotid and common carotid arteries.

Fig.36: Venous sinuses of the brain.

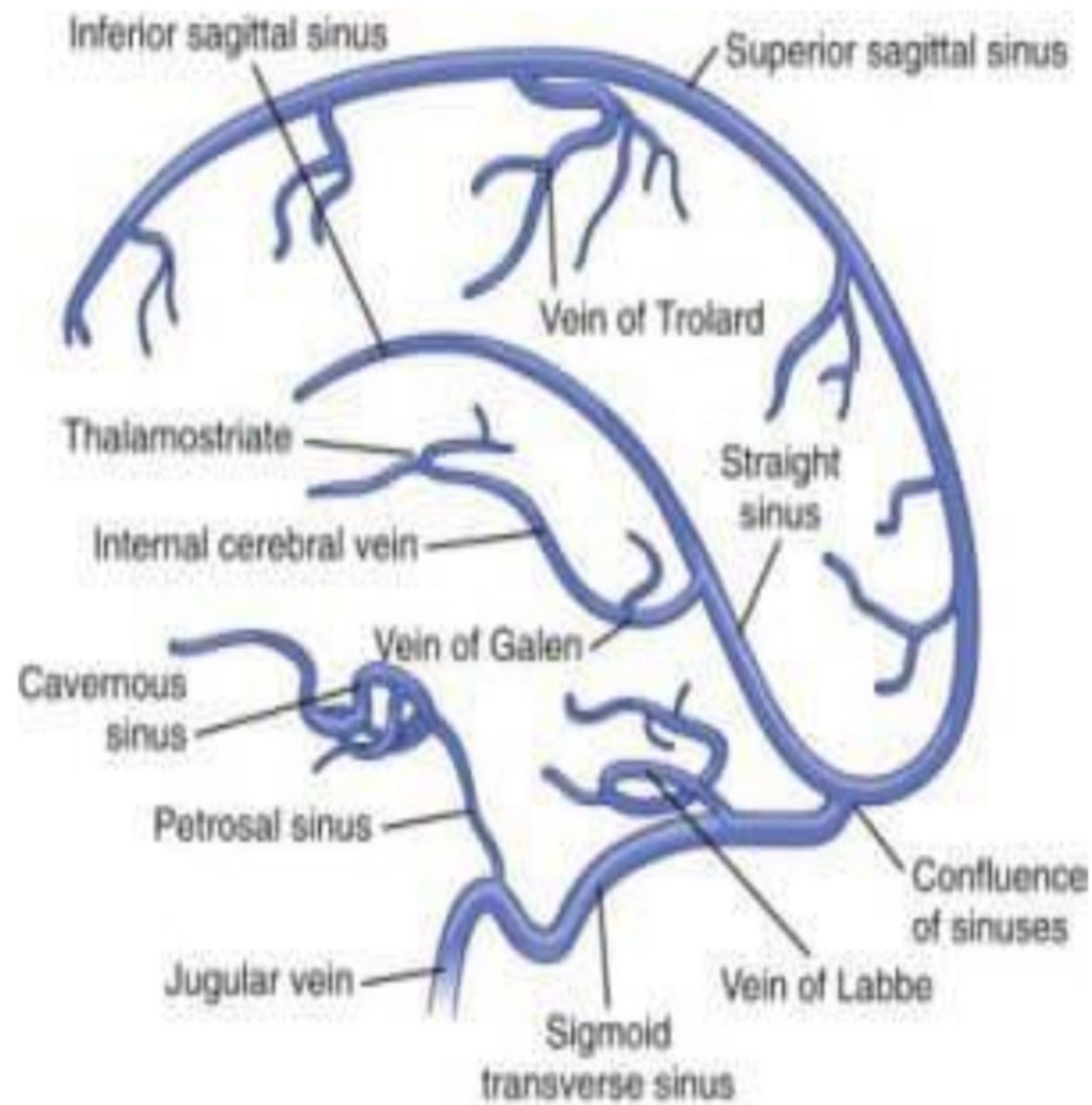

- Blood from the neck drain into IJV and the **external jugular vein**.

- The external jugular will drain into the subclavian vein. This vein will unite with the IJV to form the brachiocephalic vein.

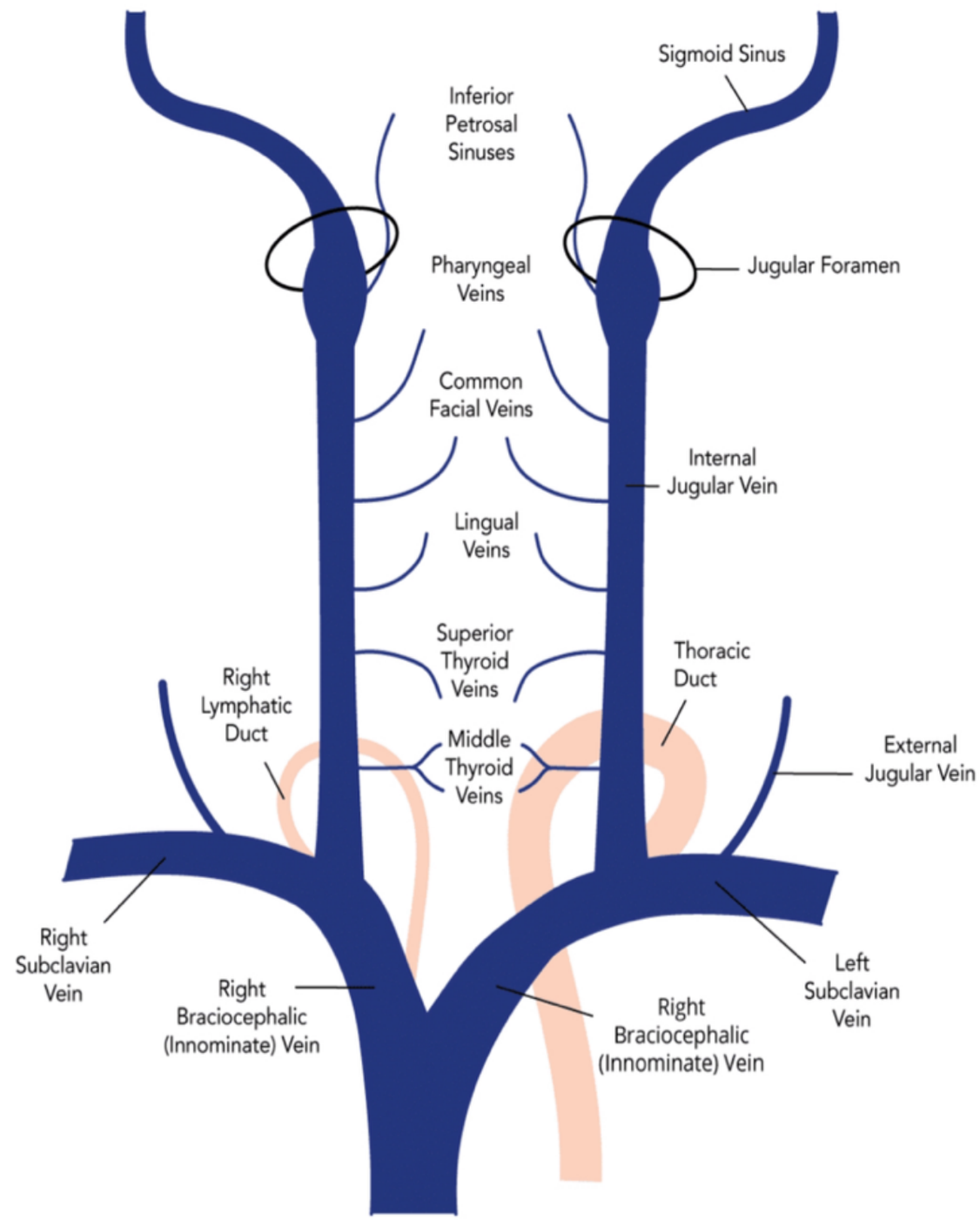

Fig.37: Internal Jugular Vein Branches.

- بالنسبة للsubclavian artery هو الشريان اللي عم بطلع واحد right وواحد left هلا الleft بطلع مباشرة منarch of aorta و الright زي الright تاعcommon carotid بطلع منbrachiocephalic artery, هلا الsubclavian artery رح يطلع عشان يغذي الupper limbs وهو طالع رح يطلع منه تفرعات هاي التفرعات وهو ماشي لحد ما يوصل upper limbs رح يطلع منه تفرعات تغذي neck زيه زي الcommon carotid رح يغذي head,thorax or chest ورح يضل مكمل as subclavian artery

- اقرب muscle للsuclavian artery هو anterior scalene , رح يكمل subclavian artery ويضل ماشي لحد ما يطلع فوق الfirst rib , كنا نحكي first rib مستحيل تتحسسها لانها جاي ورا الclavicle هلا مجرد ما الsubclavian artery طلع فوق الfirst rib بطل اسمه subclavian artery صار اسمه axillary artery
- قبل الfirst rib اسمه subclavian artery وبعد first rib صار اسمه axillary artery
هلا الaxillary artery وهي نازلة (هلا هي وظيفتها صار بدها تغذي upper limbs) فهلا وهي نازلة رح تصادف الpectoralis minor (مش major) مجرد ما صادفت الpectoralis minor رح تقسمه الي ٣ اقسام first,second, third
هلا الaxillary رح يطلع منه branches عشان يغذي منطقة الshoulder joint ، هلا وهو نازل الaxillary رح يصادف muscle اسمها teres major (مش minor يعني لا تخربطو فيهم) مجرد ما صار axillary على سوى teres major ببطل اسمه axillary artery بصير اسمه brachial artery
- بالتاني قبل teres major اسمه axillary بعد teres major اسمه brachial

- الbrachial وظيفته يغذي منطقة الarm فبالتالي رح يطلع منه branches هاي الbranches رح تغذي منطقة الarm و muscles زي triceps and biceps and brachialis كلهم هدول بمنطقة الarm , هلا رح يضل نازل الbrachial artery مجرد ما وصل عند cubital fossa اللي هو triangular depression اللي منه بمرق tendon of biceps بس مش الtendon الاصلي..الaponeuroses, زي ما حكينا قبل الtendon of biceps رح يجي على radial tuberosityورح يطلع منها aponeuroses ويروح medially باتجاه ulna ورح يمر من تحتيها median nerve and brachial artery اللي هو المكان اللي رح نحس فيه الpulse, رح يجي brachial artery بعد ما يطلع branches رح يمرق من تحت الaponeuroses of biceps بس مجرد ما مرق من عندها رح يروح lateral باتجاه radius مجرد ما وصل neck of radius رح يطلع تفرعين ، تفرع الradial artery وتفرع ulnar artery ، رح يظلوا ال٢ نازلين ويطلع منهم branches والbranches وظيفتها تغذي منطقة الforearm وفي عنا extrinsic muscles في منهم flexors and extensors

- الraduis and ulna رح يضلو نازلين لتحت بس شوي radius حتكون more superficial عشان هيك رح يبين على wrist وهاد تالت مكان بقدر احس فيه الpulse عم بحس pulse of radial artery اما ulnar بقدرش احسه لانه deep , مجرد ما وصلو هالمنطقة رح يكونو palmar arches عبارة عن اقواس اللي هي رح يطلع منها تفرعات دم مشان تغذي منطقة hand

- هسا بدها نرجع رجوع
- في عنا veins بكون superficial and deep .. اللي بهمنا هو superficial
الsuperficial رح يطلع منهم 2 superficial veins واحد اسمه basilic وواحد اسمه cephalic
طبعا في عنا ulnar and radial veins بس هدول deep (ما بهمنا)
- المهم الbasilic and cephalic رح يضلوا ماشيين superiorly لحد ما يوصلو منطقة الelbow ،
من عند منطقة elbow رح يجي vein لحاله اسمه medial cubital vein رح يجي يتحد مع
basilic ومع الcephalic (الcephalic ماشي lateral والbasilic ماشي medially) فعشان
هيك هون اسهل مكان لسحب الدم لانه عندي cephalic and basilic and medial cubital vein
مجرد ما اتحد basilic مع medial cubital vein رح يكملوا لفوق as basilic and cephalic رح
يضلو طالعين لفوق لمنطقة الarm لحد ما يوصلو على level teres major muscle هو المكان اللي
تحولت فيه axillary الى brachial ،بهاد المكان رح يجي عنا vein لحاله اسمه brachial vein
ورح يتحد مع basilic ويصير اسمه axillary vein , طبعا cephalic ماشي لحاله
فمجرد ما تجاوزت teres major بصير اسمه axillary vein, رح يكمل لفرق وتيجي تتحد معه وقتها
الcephalic vein وبضلو مكملين مع بعض لحد ما يوصلو منطقة الfirst rib , فببطل اسمه
axillary vein بصير اسمه subclavian vein رح يكمل شوي رح ينزل عليه external jugular
vein بكمل شوي بدخل عليه internal jugular vein بعدين بصير اسمه brachiocephalic vein

Major Blood Vessels of the Upper Limb

The Major Arteries

The Axillary Artery

- It's the direct continuation of the subclavian artery when it passes the lateral border of the first rib.
- The pectoralis minor muscle divides the artery into 3 part.
- Its several branches supply surrounding structures.
- At the lower border of the teres major muscle, it becomes the brachial artery.

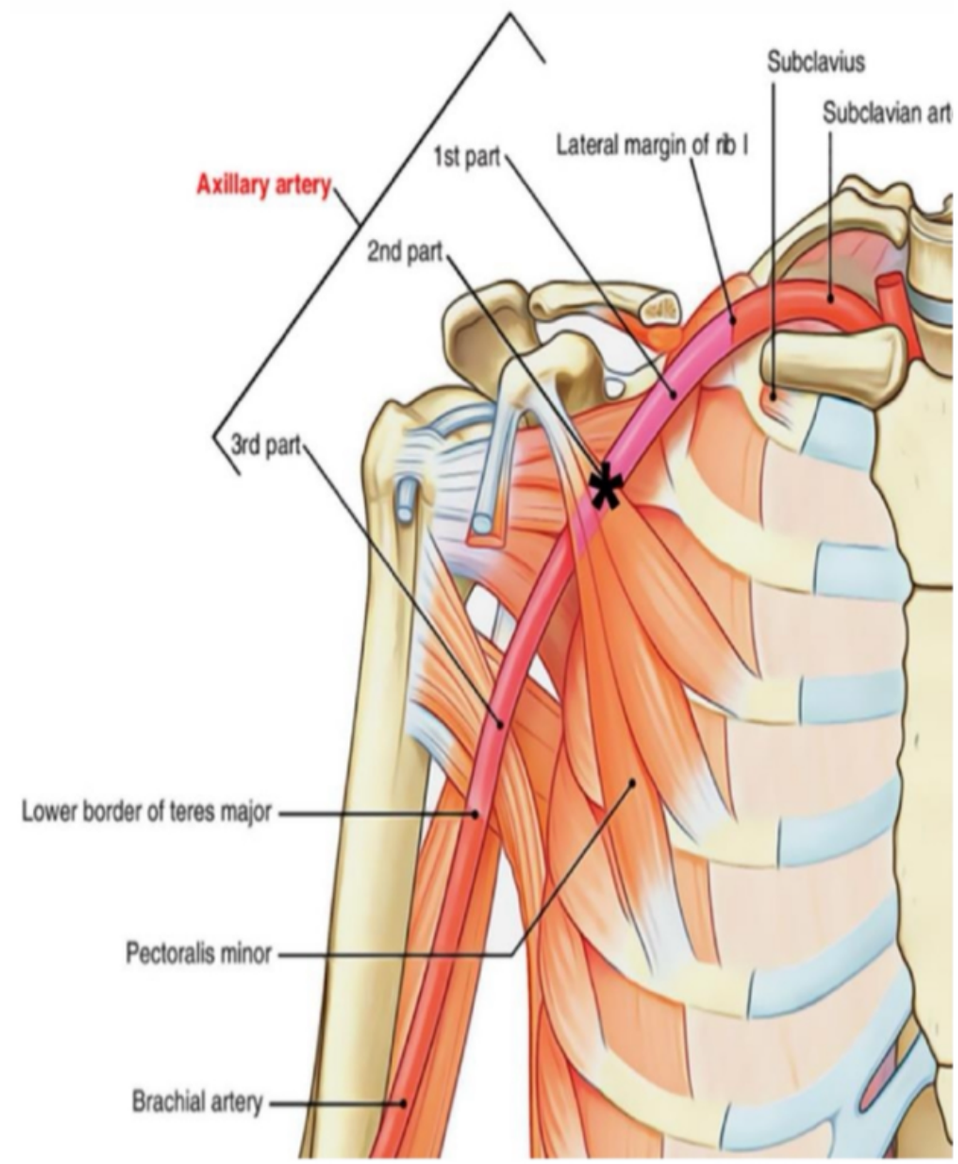

Fig.38: The axillary artery.

The Brachial Artery

- The direct continuation of the axillary artery when it passes the lower border of the teres major muscle. Its branches supply surrounding structures.
- It terminates at the neck of the radius by dividing into the radial and ulnar arteries.
- In the cubital fossa, the brachial artery passes medial to the tendon of the biceps muscle where it's superficial. This is the site for taking the brachial pulse and measuring the blood pressure.

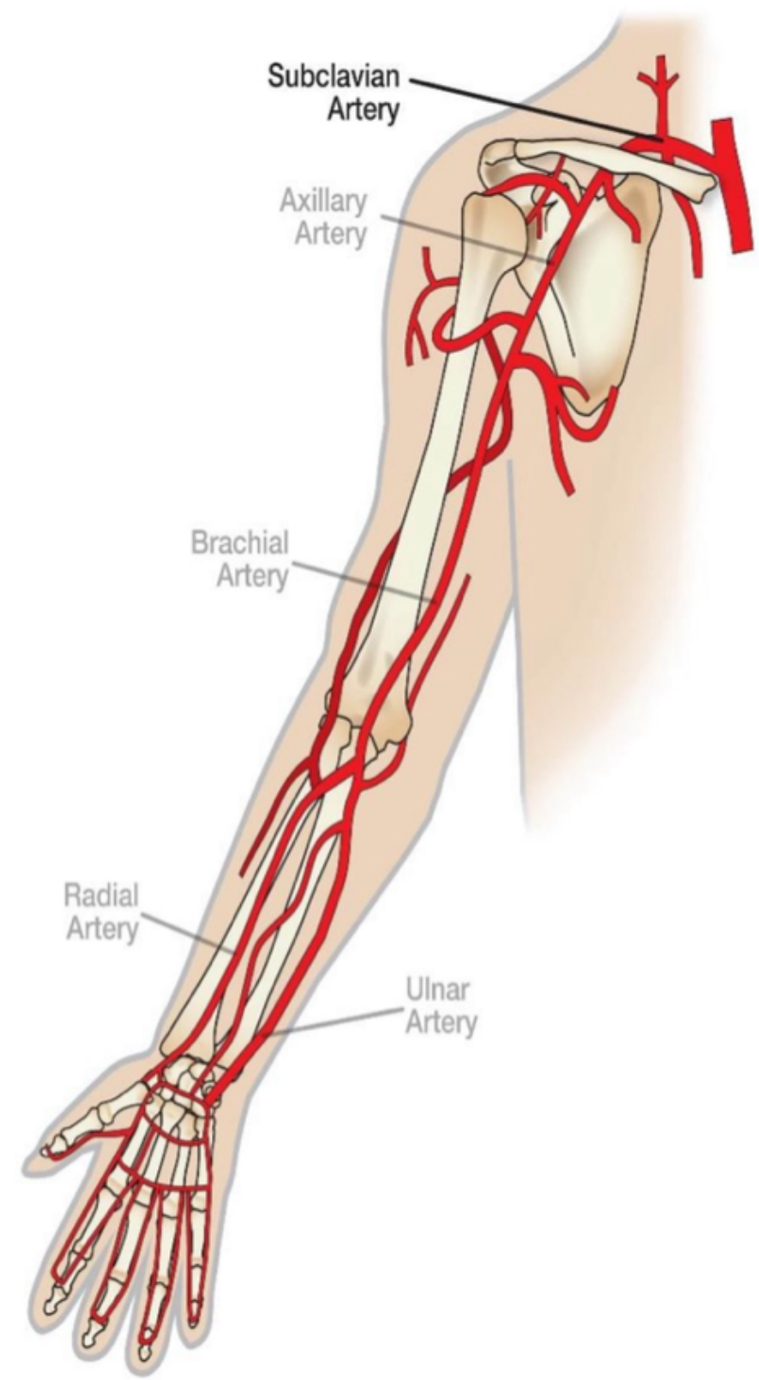

Fig.39: The brachial artery in the cubital fossa.

The Radial and Ulnar Arteries

- The radial artery passes down on the lateral aspect of the forearm. The ulnar passes on the medial side. The radial and ulnar arteries supply structures in the forearm.
- They enter the palm where they form the superficial and deep palmar arches. The two palmar arches supply structures in the hand and fingers.
- The radial artery is superficial as it passes over the wrist. It's here that the radial pulse can be felt.

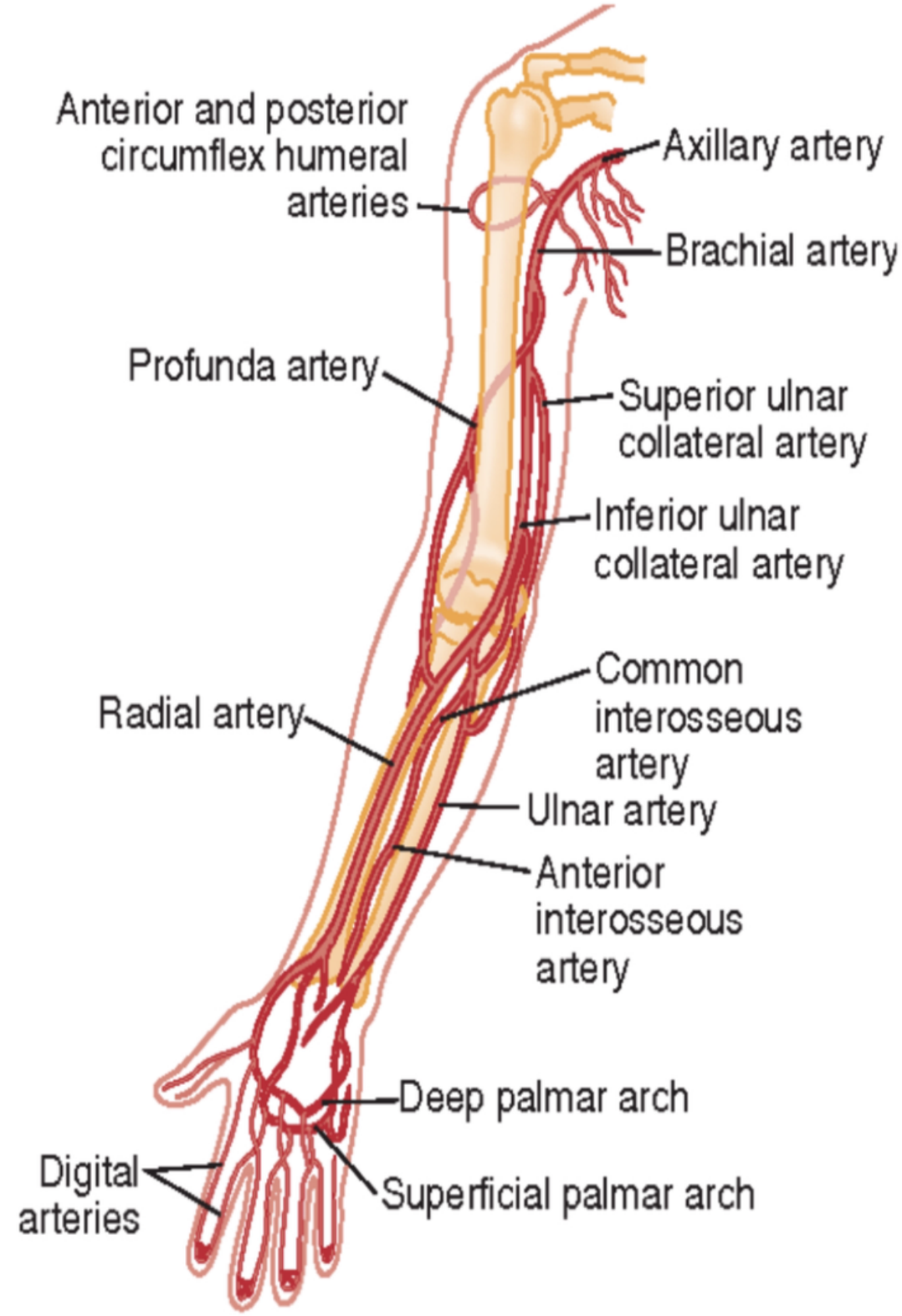

Fig.40: Arteries of the upper limb.

The Major Veins

- In the upper limb, we have superficial and deep veins. The **superficial veins** run just under the skin. They start as a network on the dorsum of the hand. From this network the **cephalic and basilic** veins arise. These two superficial veins are connected at the elbow by the **median cubital vein**. Superficial veins are used to take blood samples.
- The basilic vein unites with the median cubital vein and continue as basilic vein in the arm. The basilic vein in the arm unites with the brachial vein to form the axillary vein (a large deep vein accompanying the axillary artery). This will join with the cephalic vein. Upon passing the outer border of the first rib, the axillary vein becomes the subclavian vein.

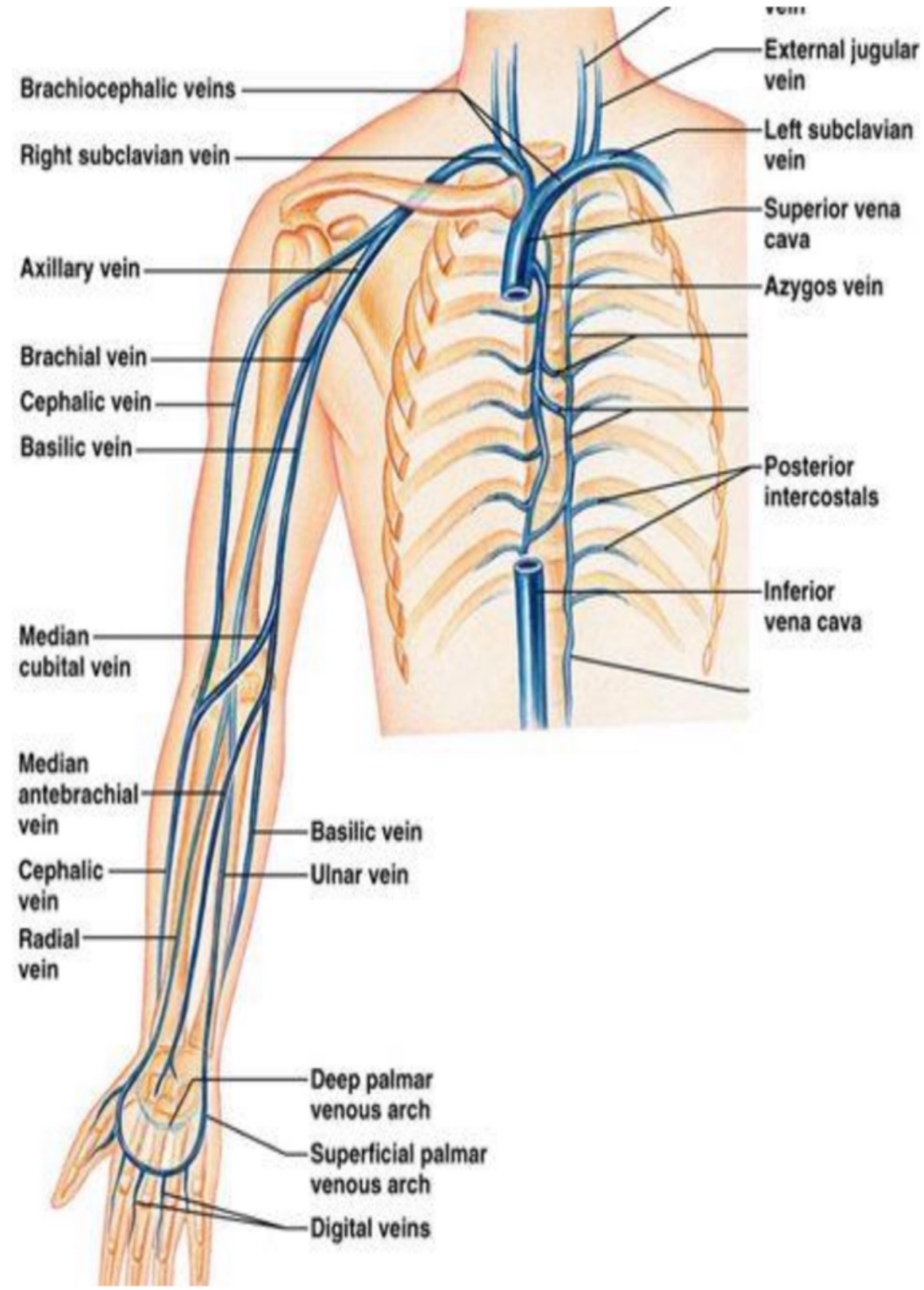

Fig.41: Veins of the upper limb.

Major Blood Vessels of the Abdomen

The Major Arteries

The Abdominal Aorta

- The abdominal aorta is the continuation of the descending thoracic aorta. It **begins** where the aorta passes through the diaphragm to enter the abdominal cavity opposite **T12** vertebra.

- The abdominal aorta is closely related to the vertebral column and the IVC.

- It **terminates** opposite **L4** by dividing into the two Common Iliac Arteries.

left and right

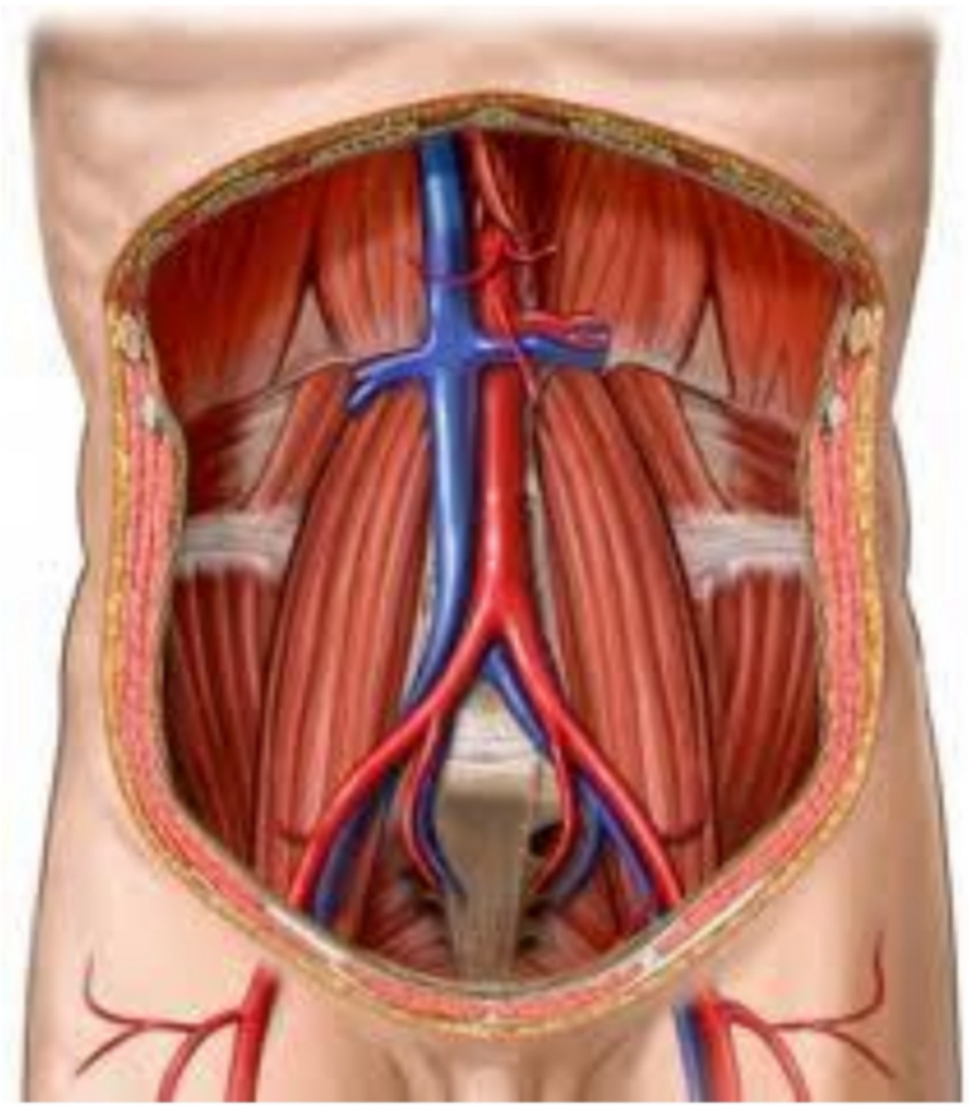

Fig.42: The abdominal aorta and the inferior vena cava.

Branches

- Celiac trunk, superior mesenteric artery, and inferior mesenteric artery which supply organs of the digestive system in the abdomen.
- Suprarenal arteries supply the adrenal gland.
- Renal arteries supply kidneys.
- Others.

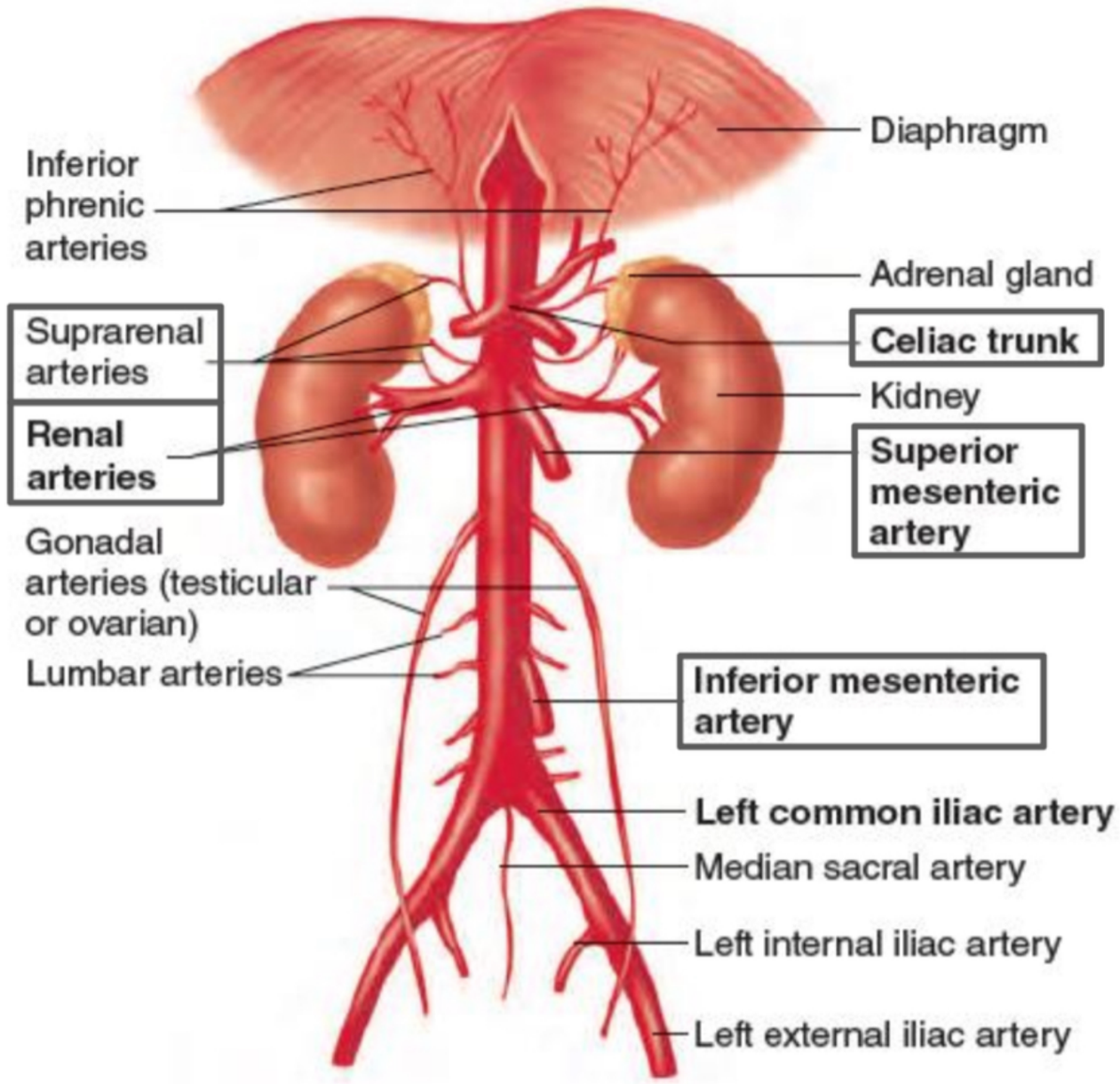

Fig.43: Branches of the abdominal aorta.

The Major Veins

- All Blood from the abdomen drains ultimately into the IVC.
  Inferior vena cava

- The IVC passes upwards close to the abdominal aorta, then passes through the diaphragm at level of **T8** to enter the thorax where it opens into the RA.
  بدخل من

- The blood from the digestive organs (esophagus, stomach, small and large intestines, liver, pancreas and spleen) drains first into the **Portal vein** then into the IVC.
  لازم يدخل على liver بالأول

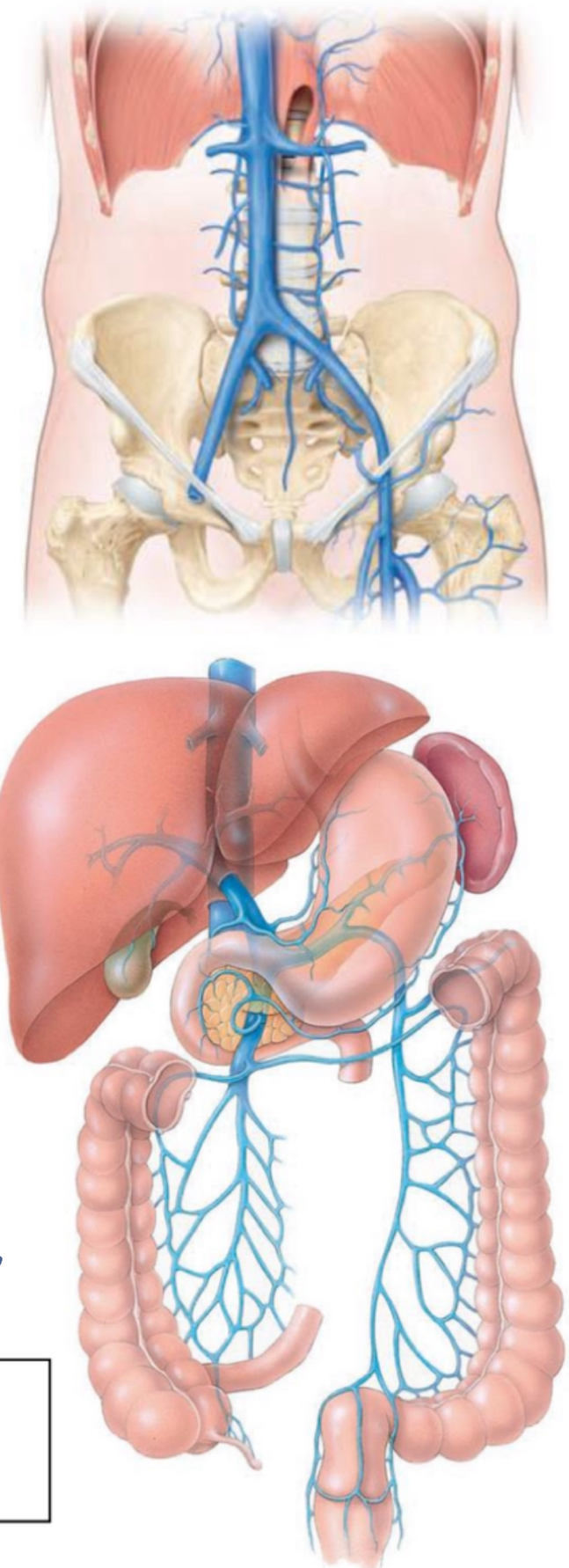

Fig.44: The inferior vena cava (above) and the portal vein (below).

Major Blood Vessels of the Lower Limb

The Major Arteries

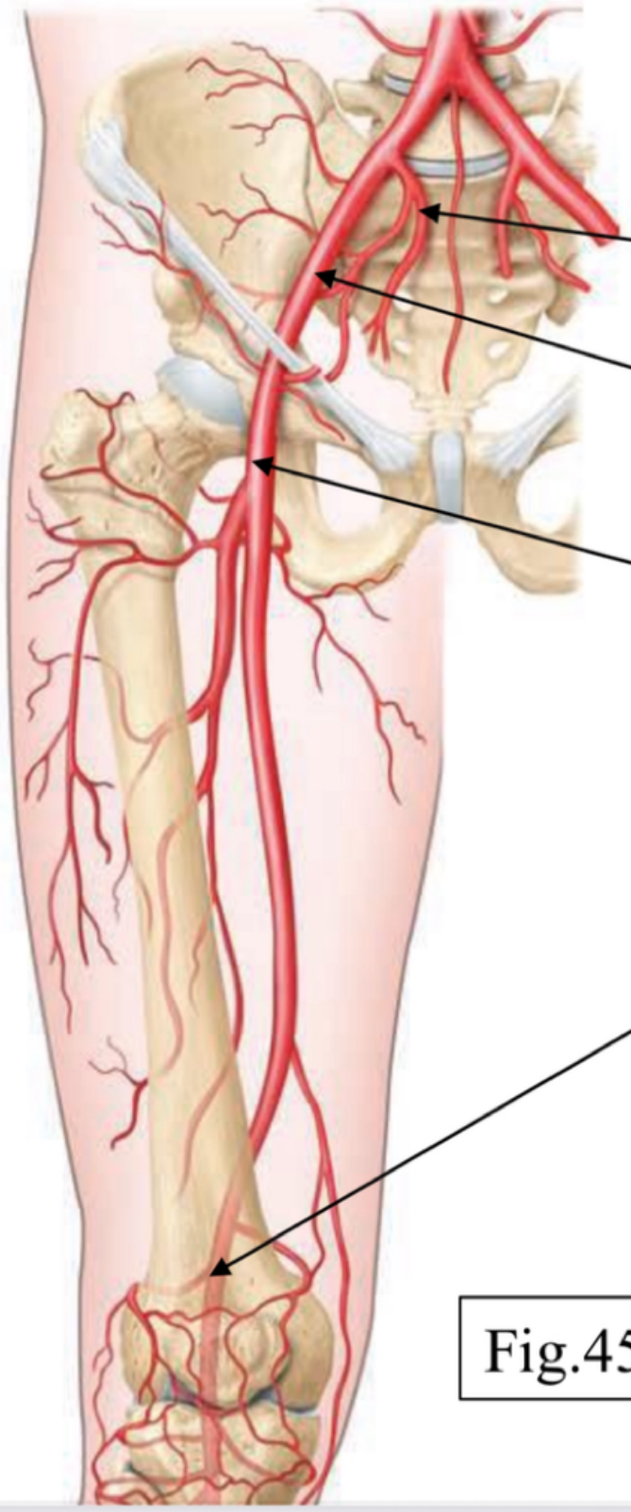

- Each common iliac artery soon divides to give the internal and external iliac arteries.
- The **internal iliac artery** supplies structures in the pelvis. بغذي
- The **external iliac artery** passes into the thigh where it becomes the femoral artery. بغير اسمه
- The **femoral artery** gives branches that supply structures in the thigh and the knee joint. بغذي
- When this artery reaches the knee joint it becomes known as the **popliteal artery**. The branches of this artery supply structures in the leg and foot. بغير اسمه بغذي

Fig.45: Major arteries of the lower limb.

The Major Veins

- ✓ Here we have superficial and deep veins.

بهمنا أكثر من Deep

- ✓ The superficial veins are:

a. The **Great Saphenous vein** which drains into the femoral vein.

b. The **Small Saphenous vein** which drains into the Popliteal vein.

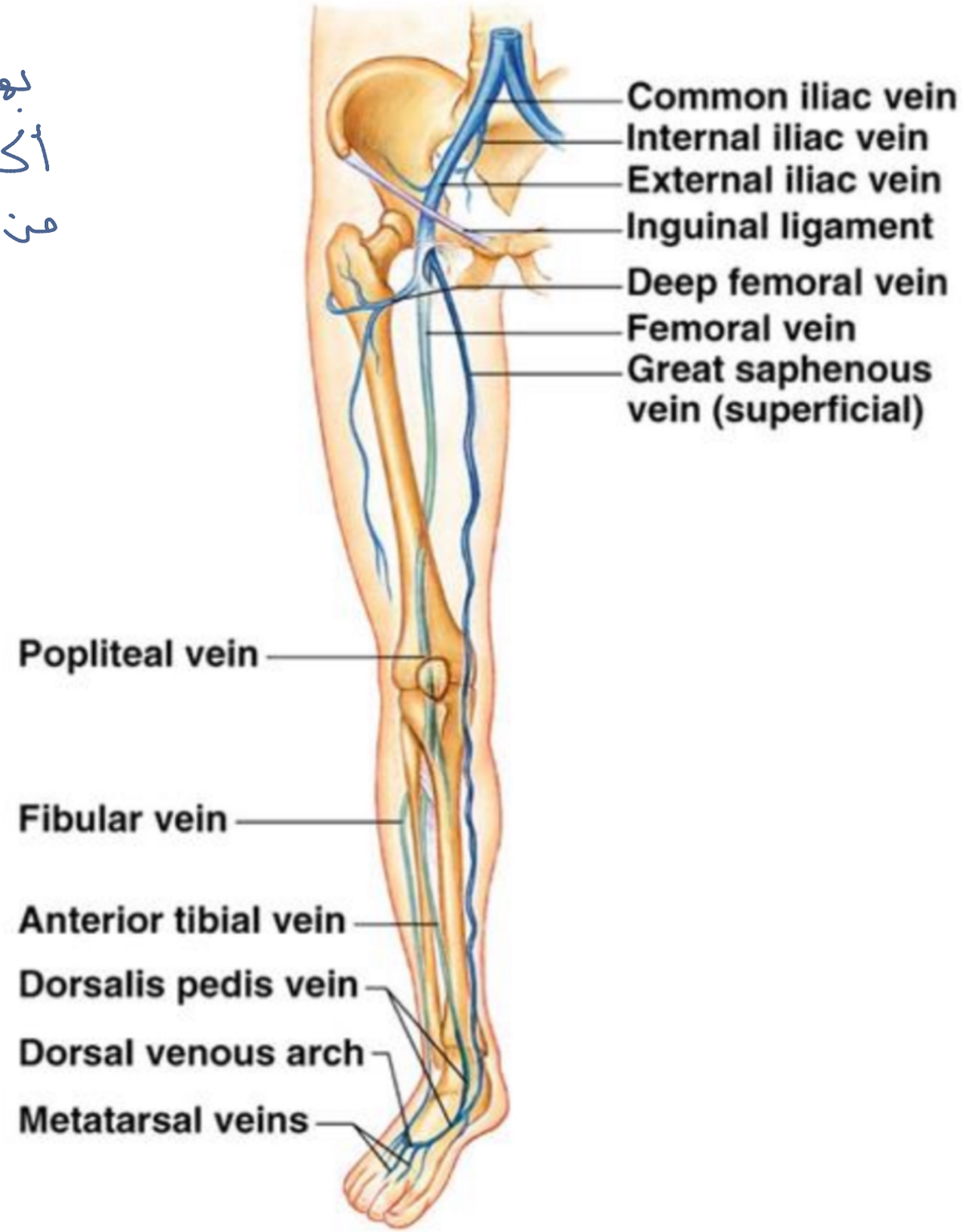

Fig.46: Major veins of the lower limb.