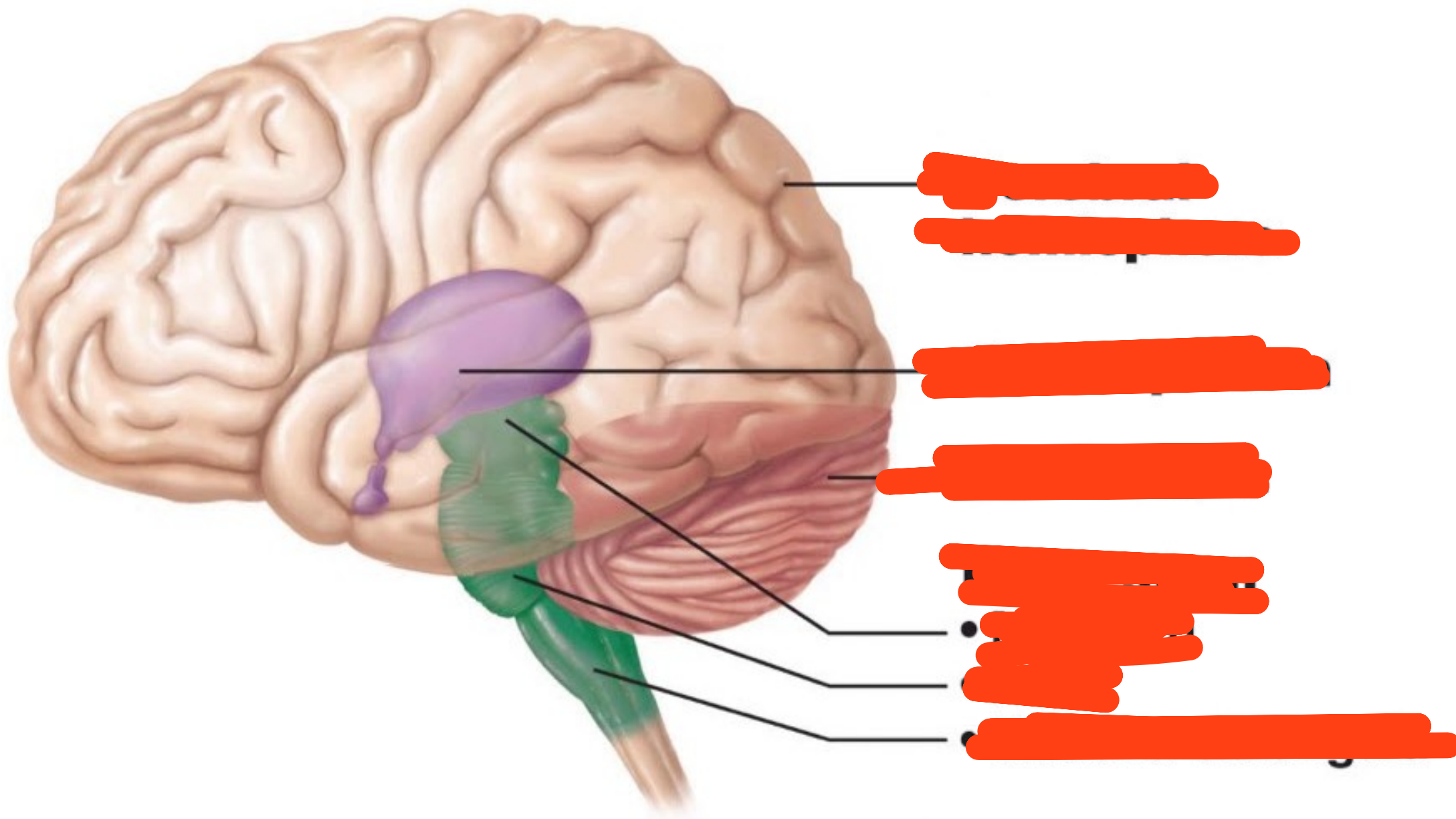
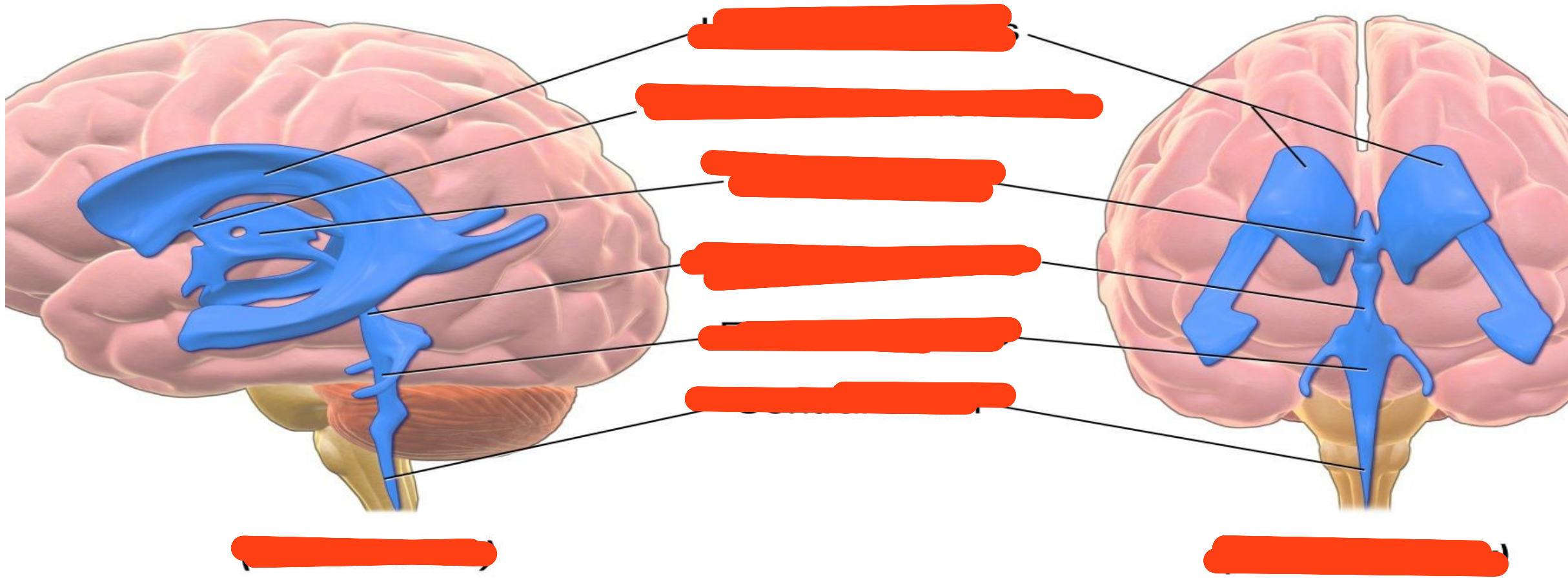
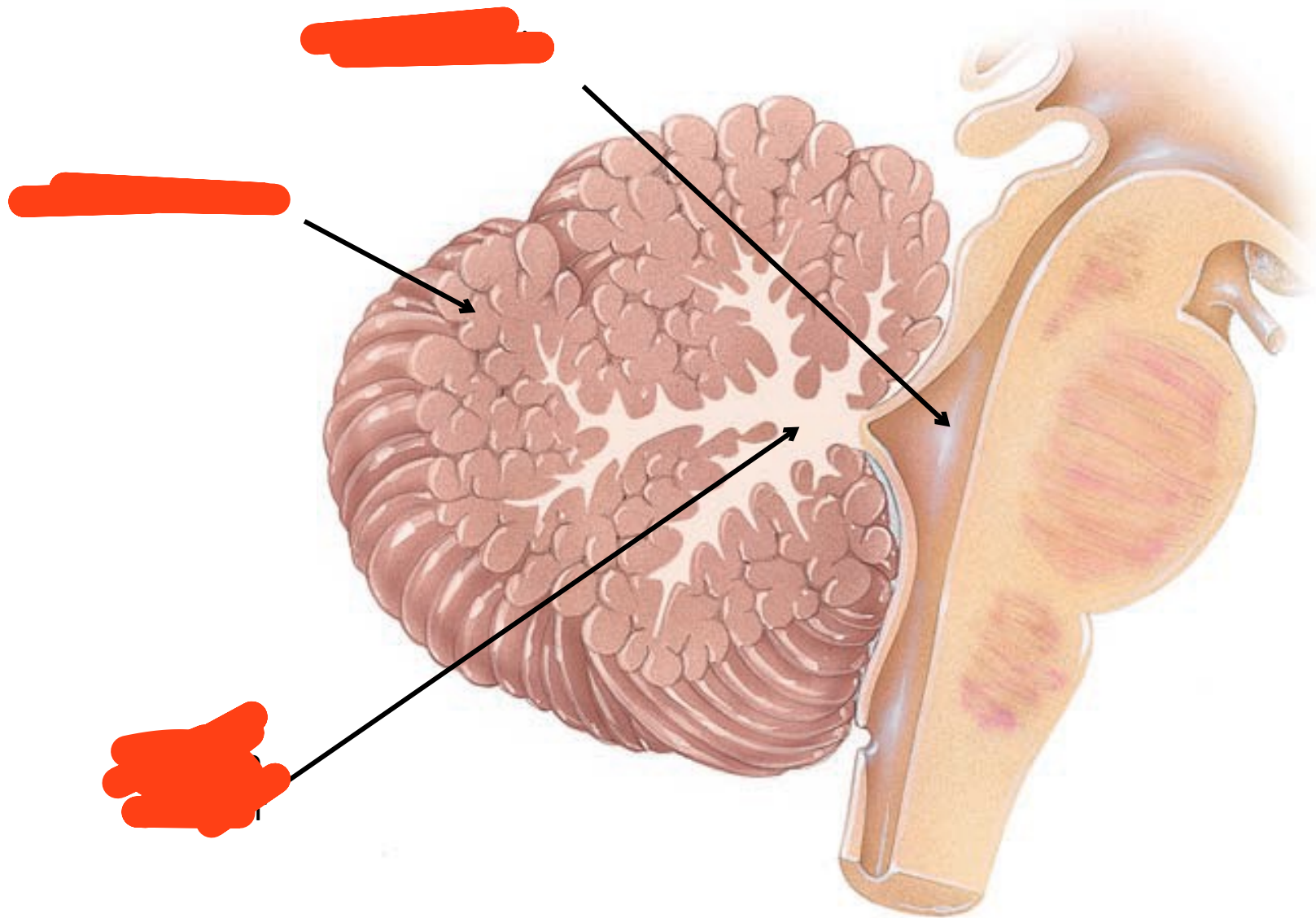
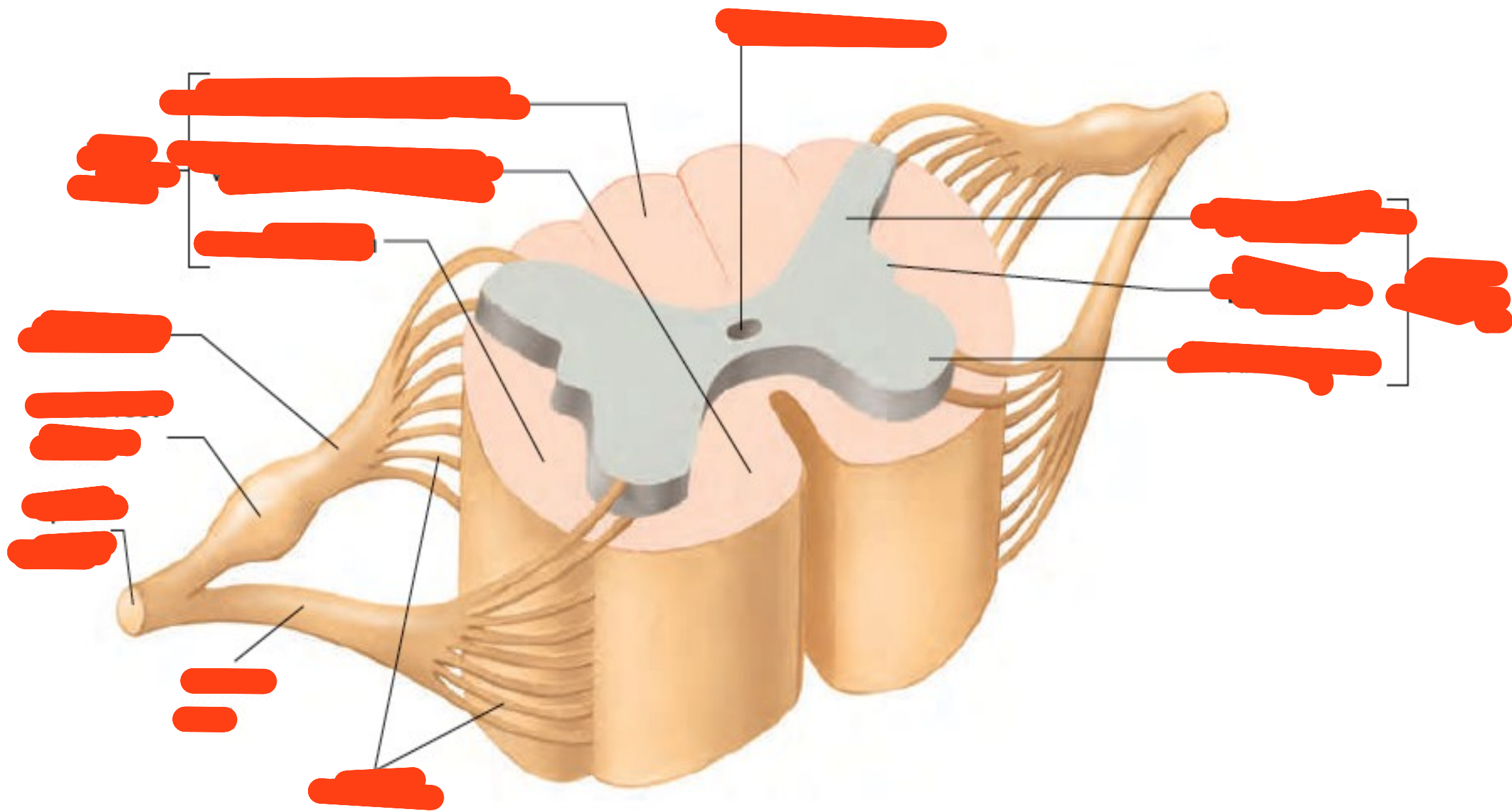


Anatomy and Histology lab
exam pictures



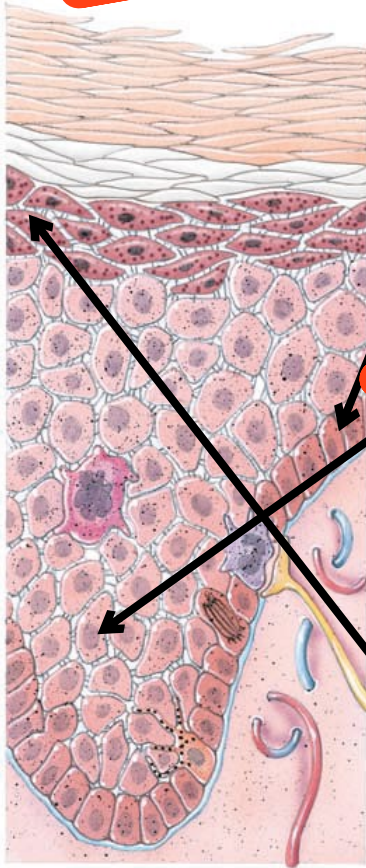






[REDACTED]

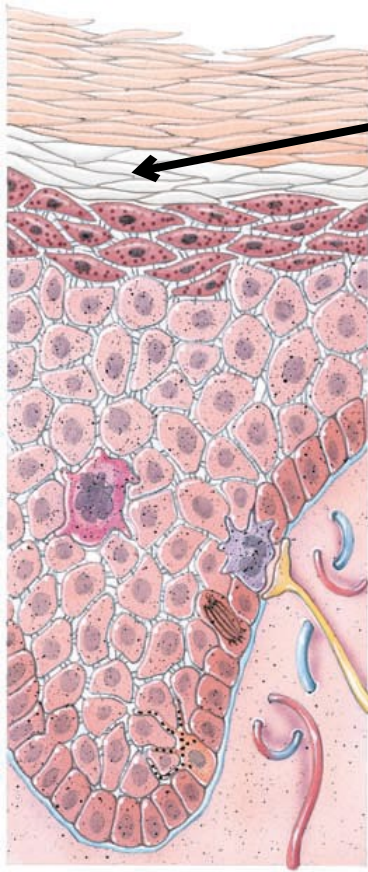
[REDACTED]
[REDACTED]
[REDACTED].



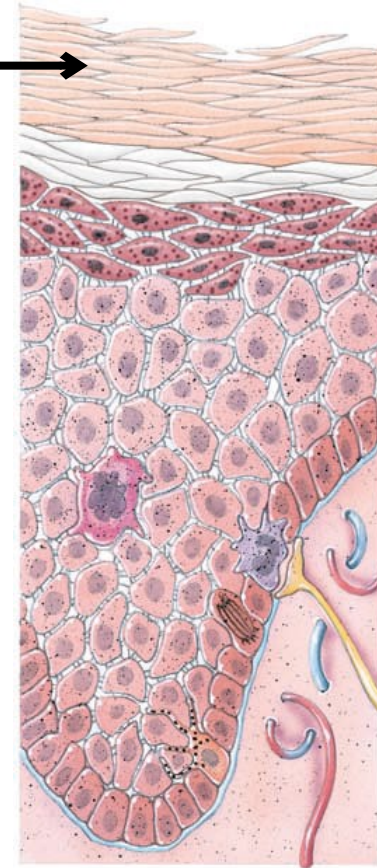
[REDACTED]

[REDACTED]

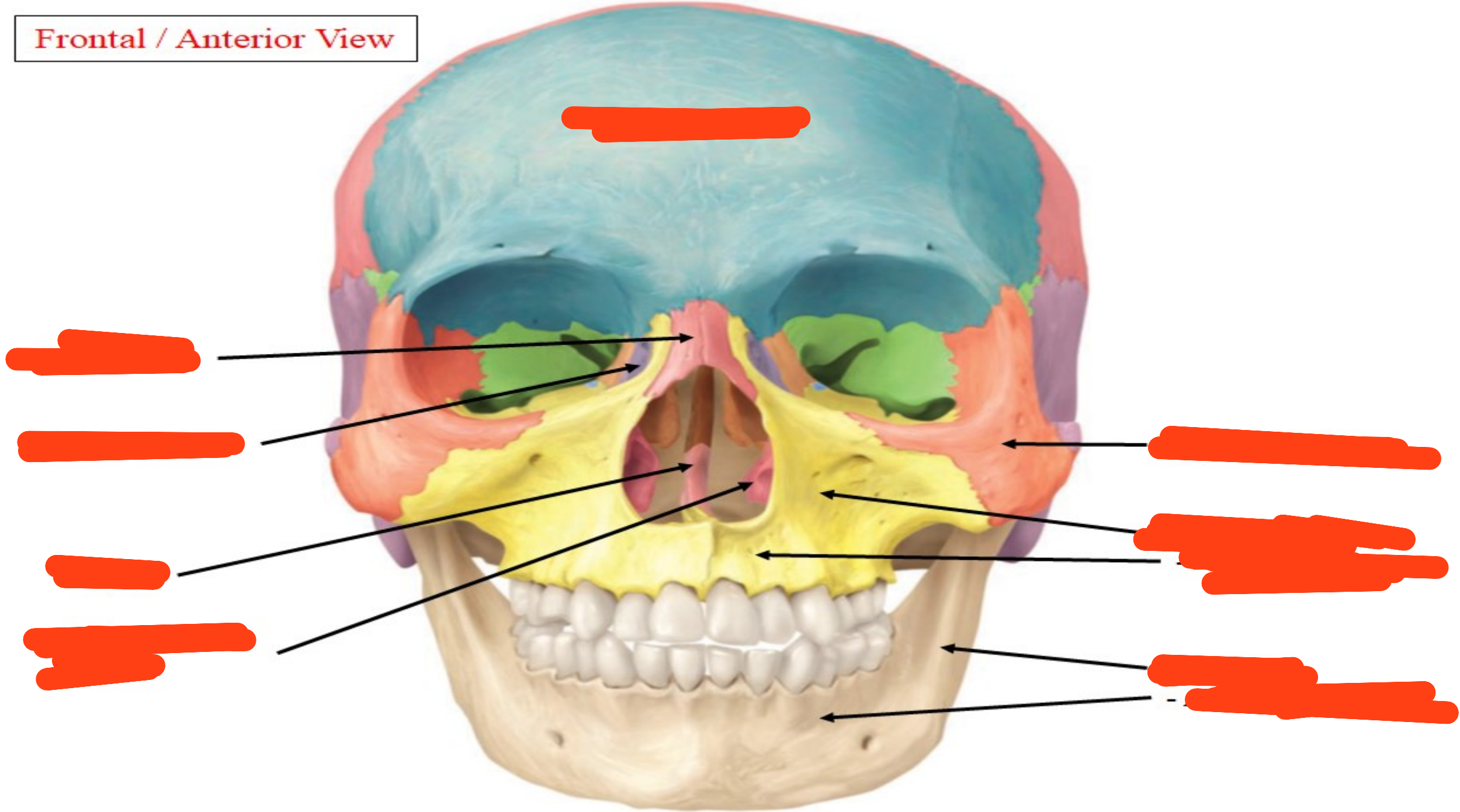
[REDACTED]



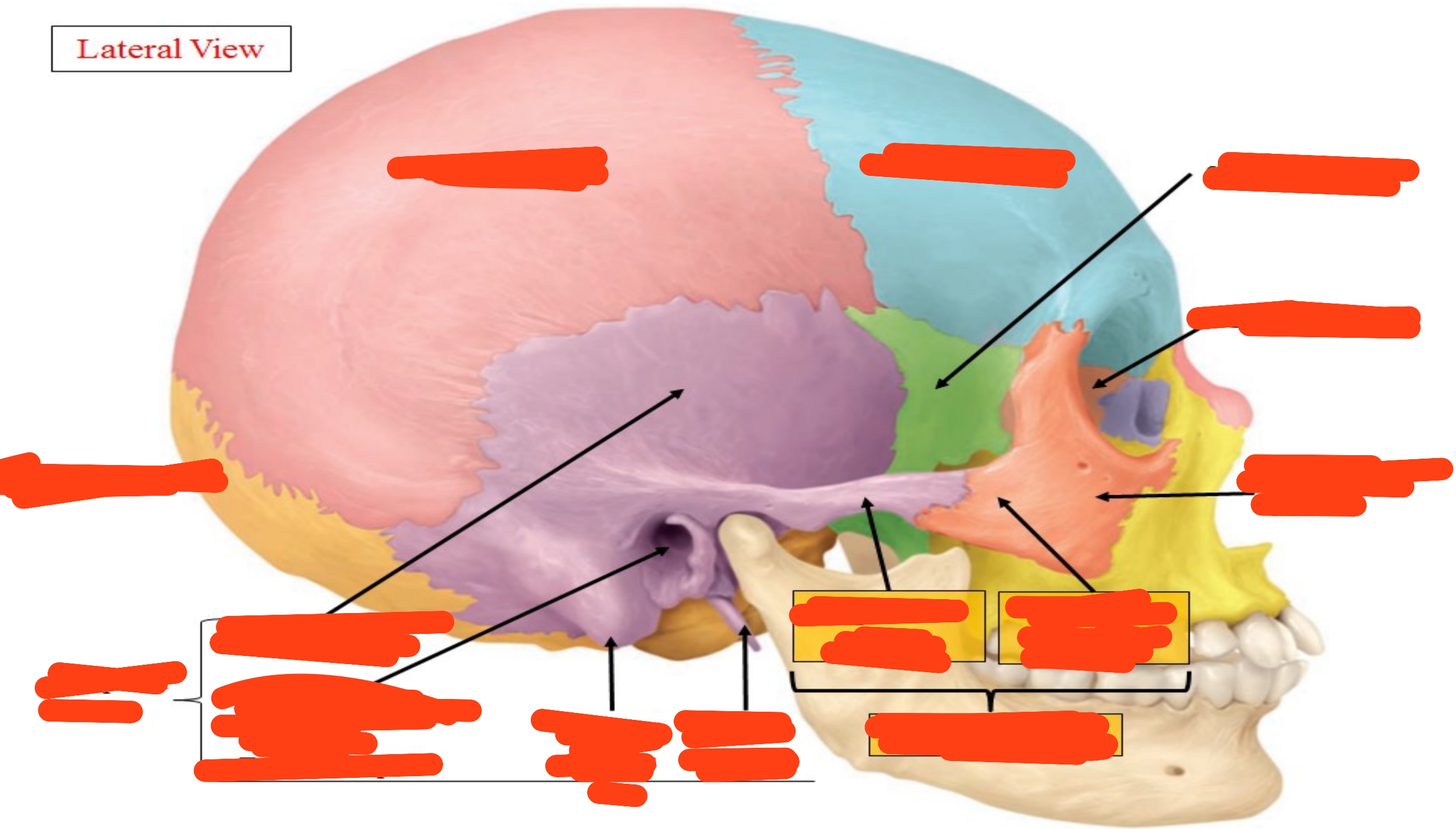
[Redacted text]

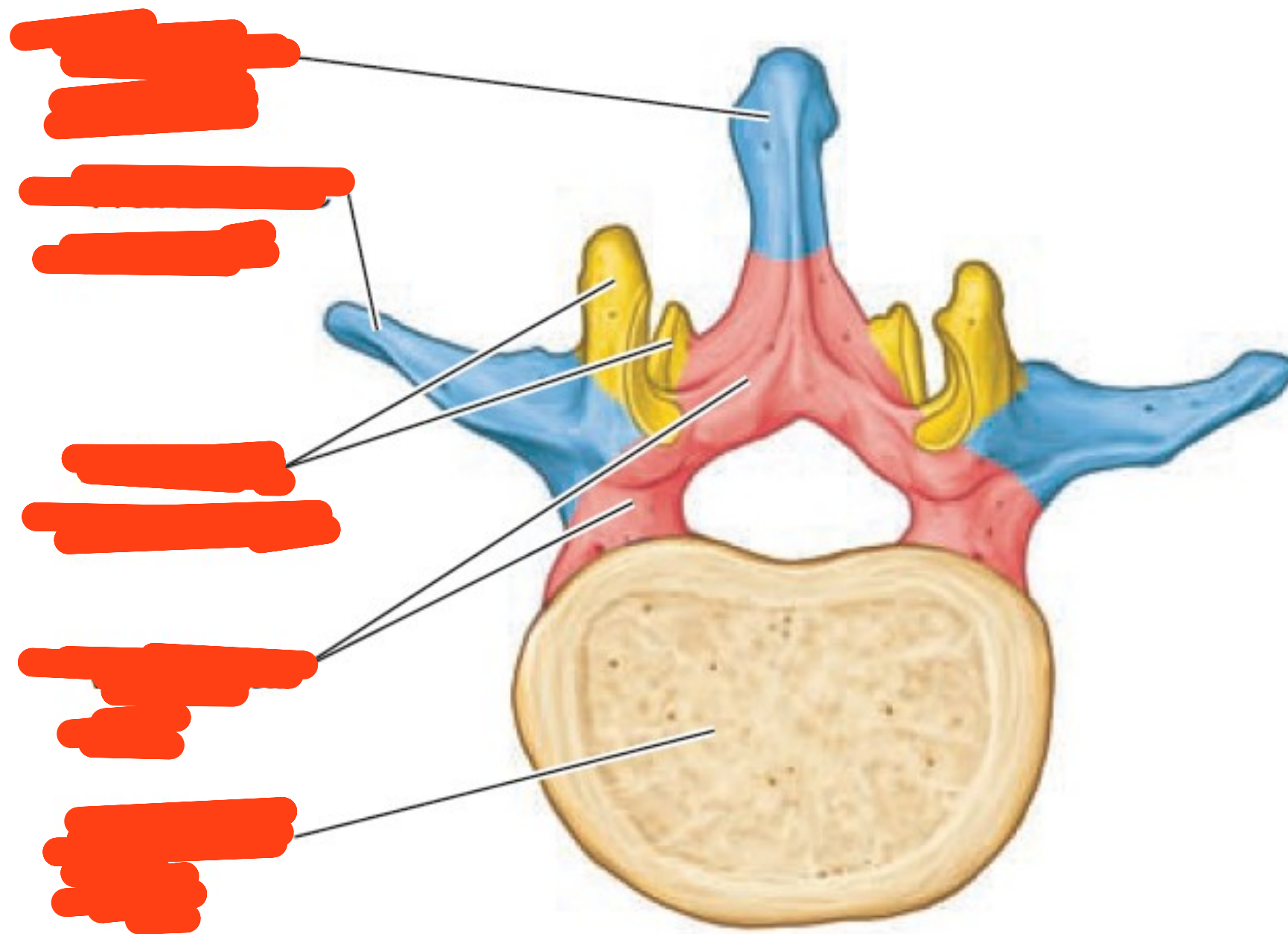


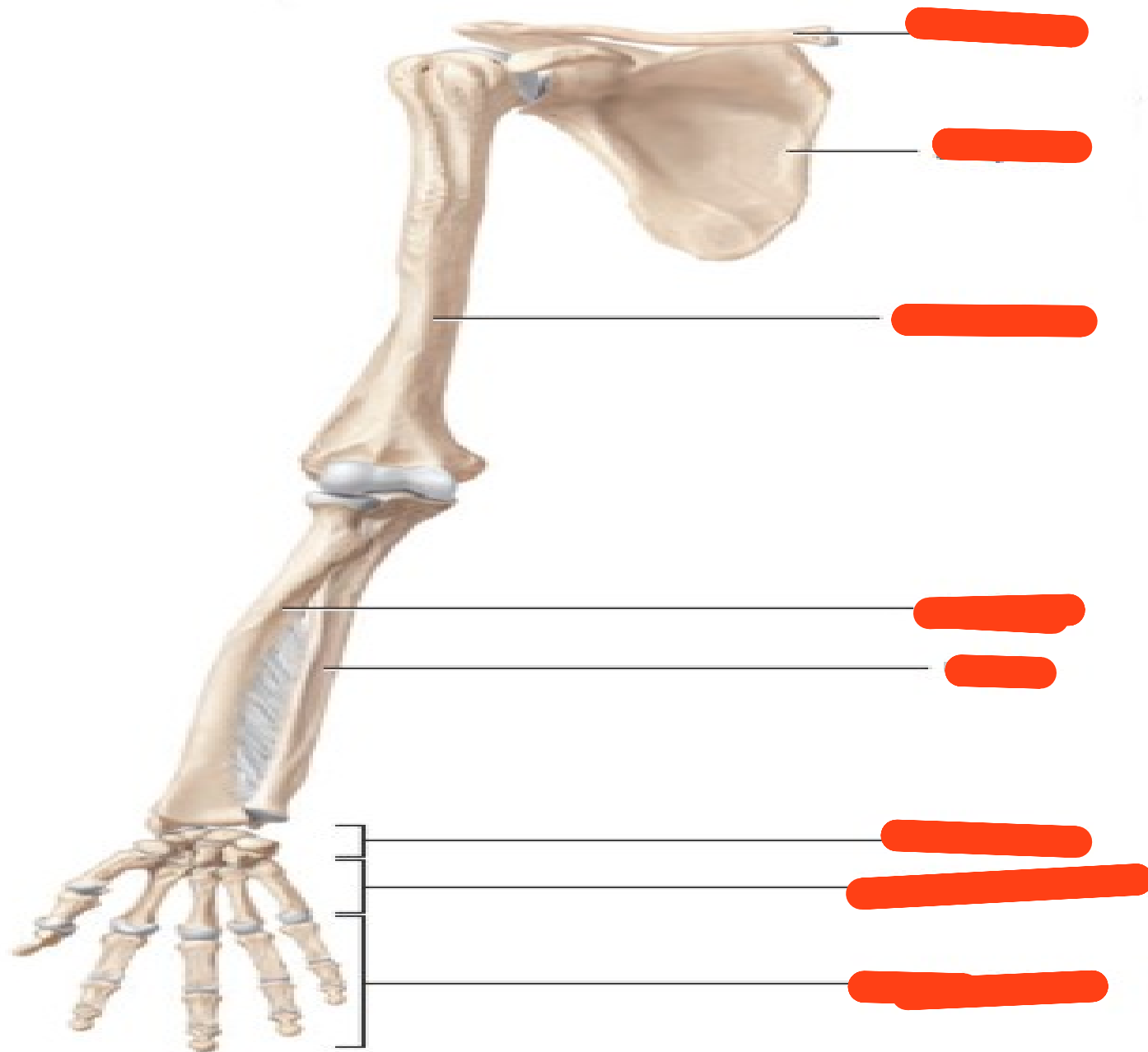
Frontal / Anterior View



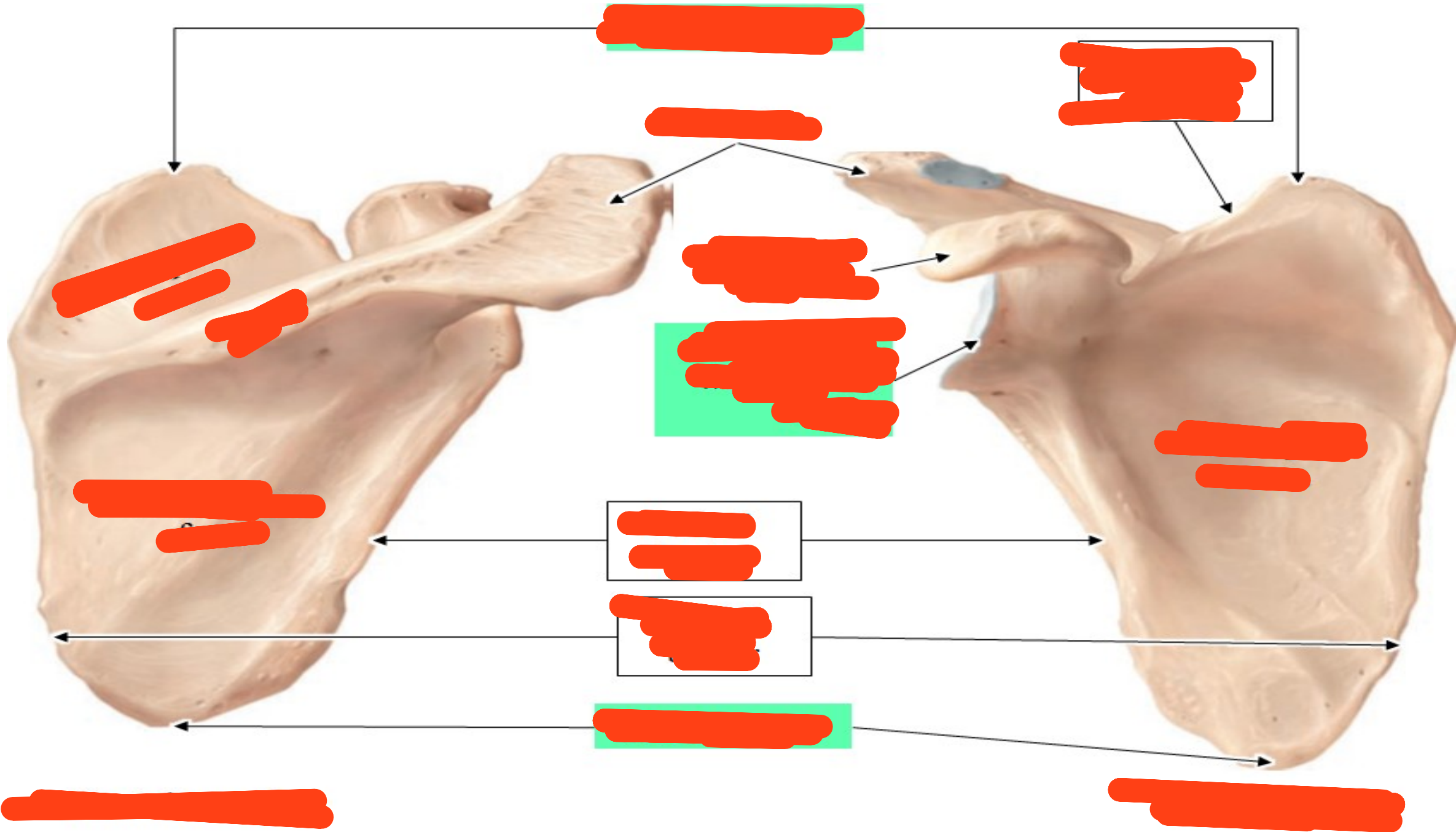
Lateral View



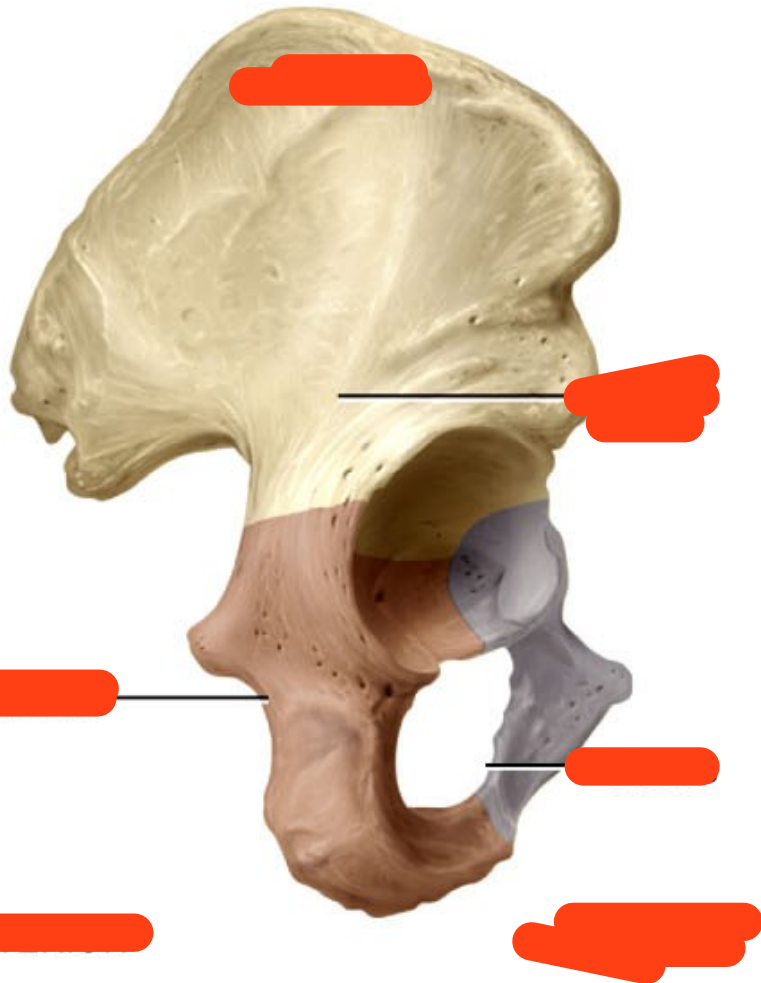




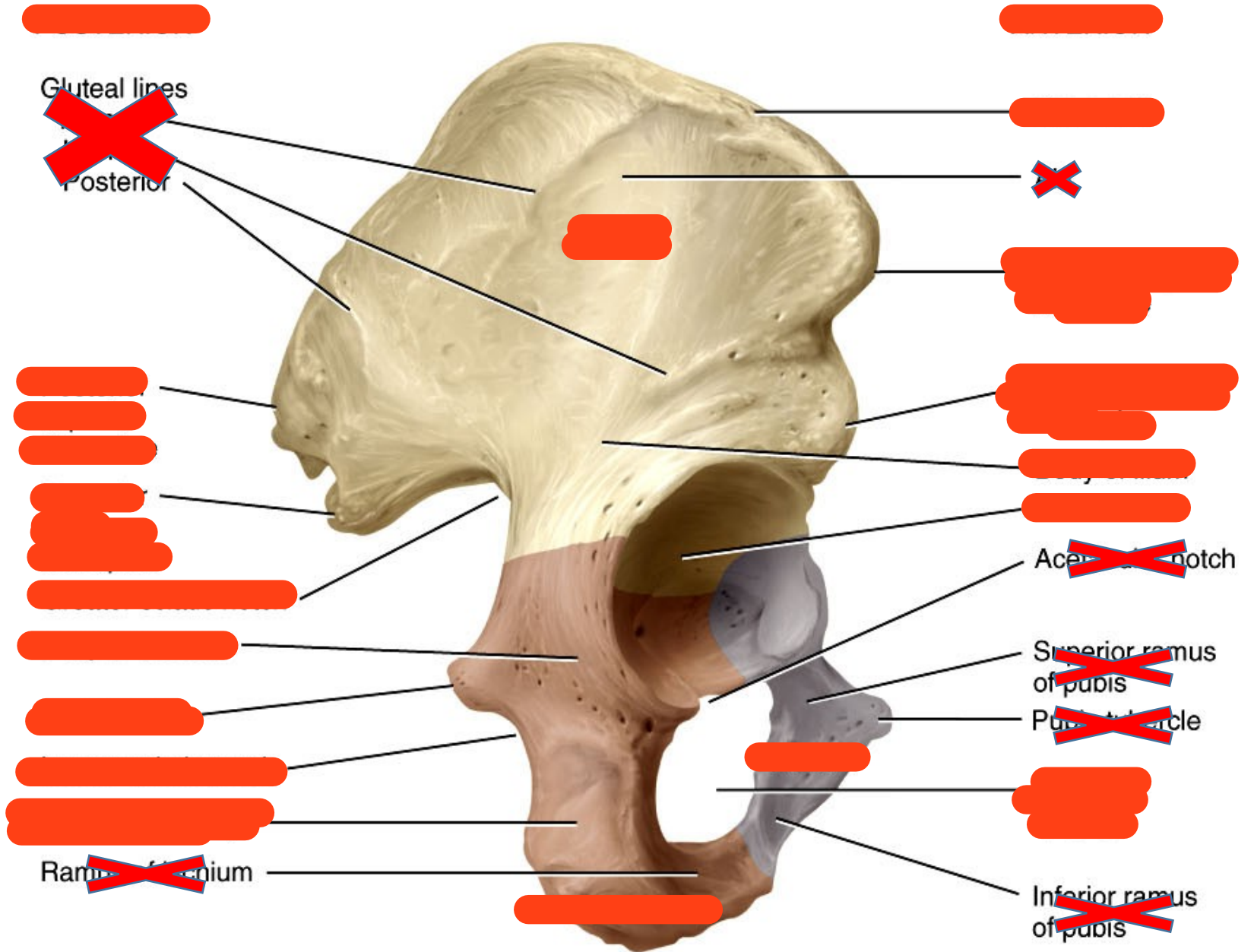
Anterior view of free upper limb



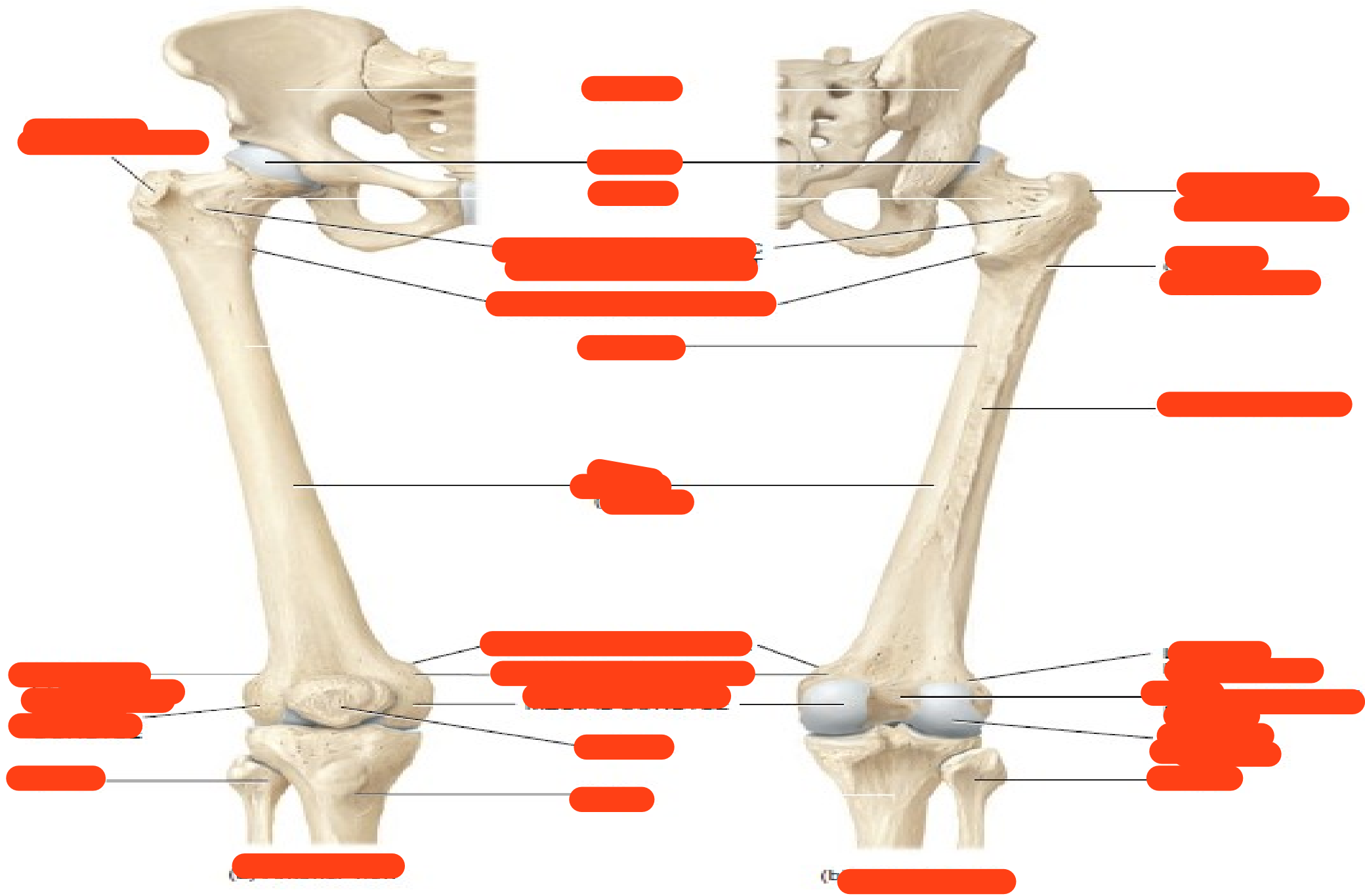


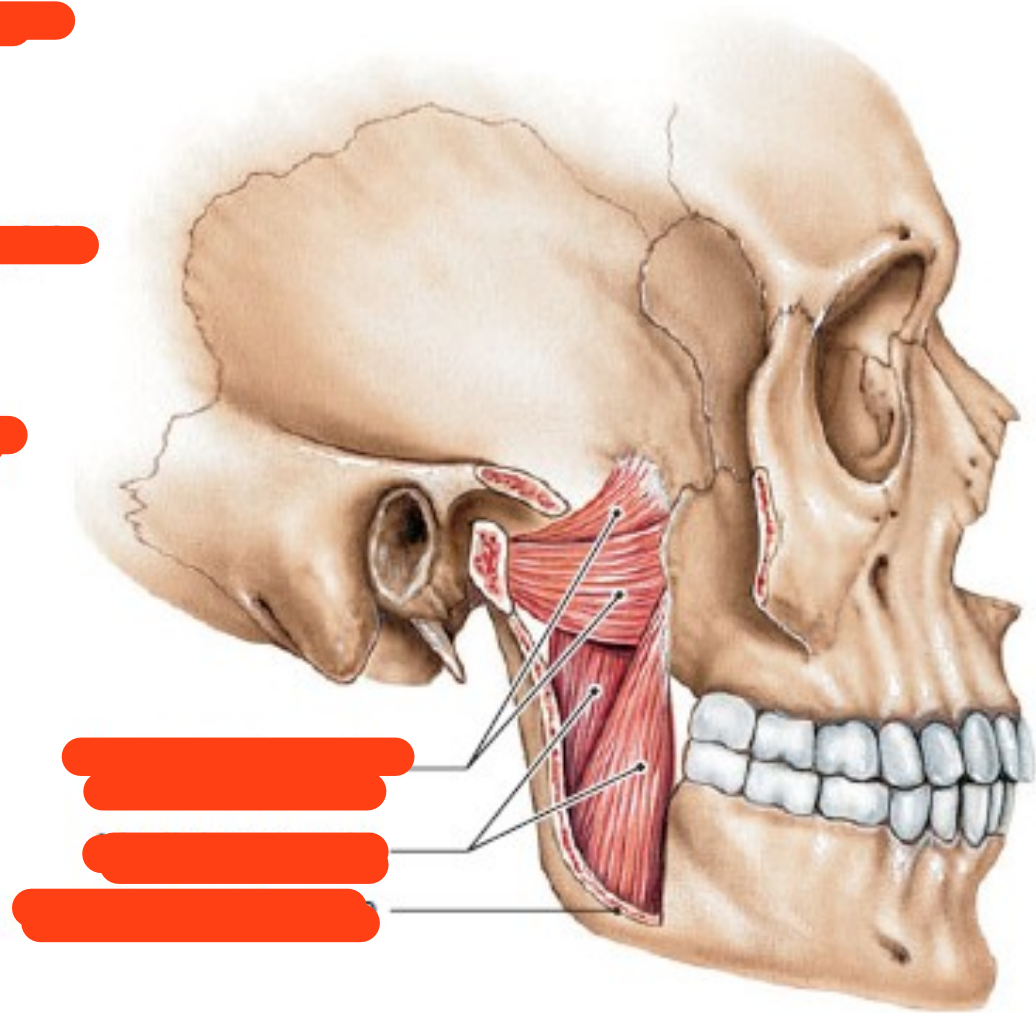
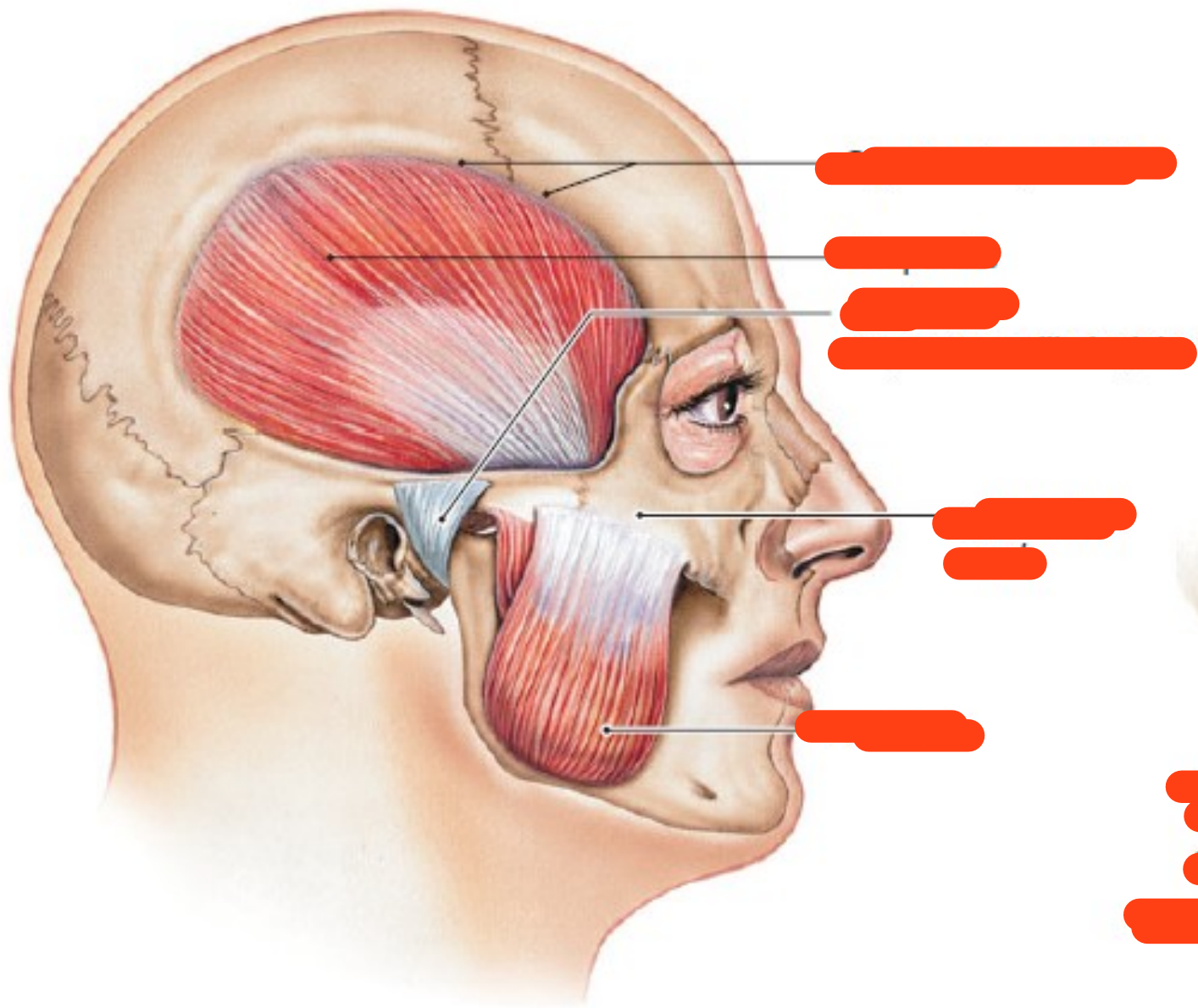


(a) Lateral view showing parts of hip bone



(b) Detailed lateral view





- [redacted]
 - 1. [redacted]
 - 2. [redacted]
 - 3. [redacted]
-
- [redacted]
 - 1. [redacted]
 - 2. [redacted]
 - 3. [redacted]

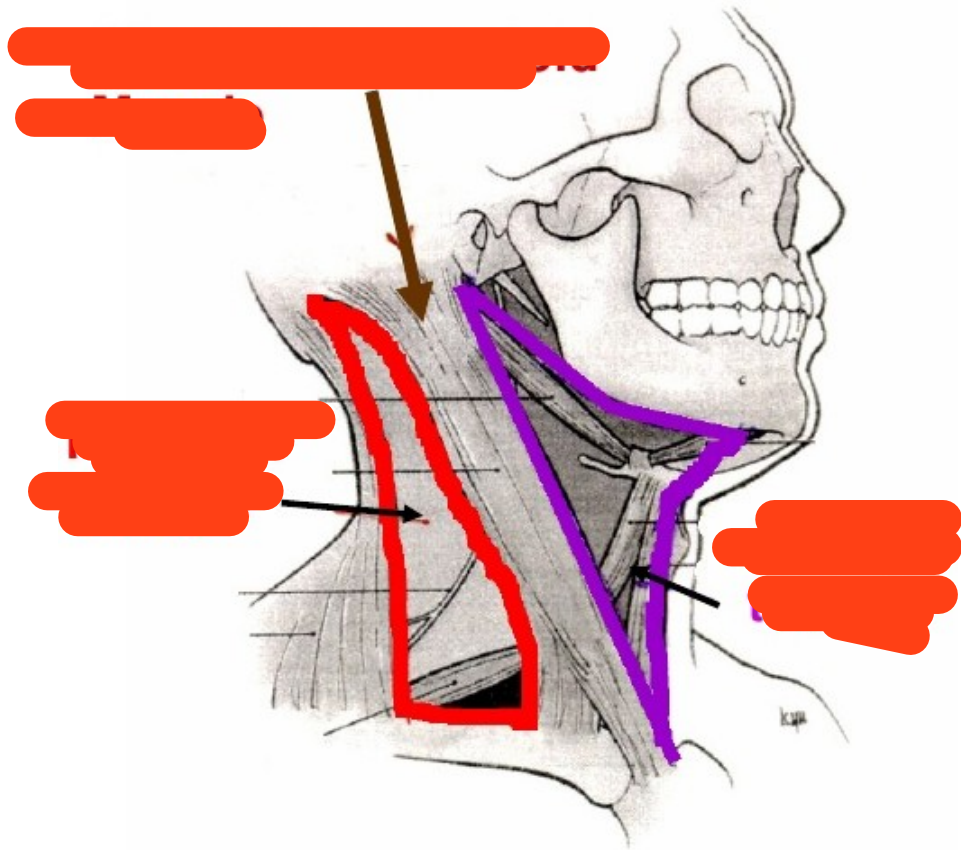
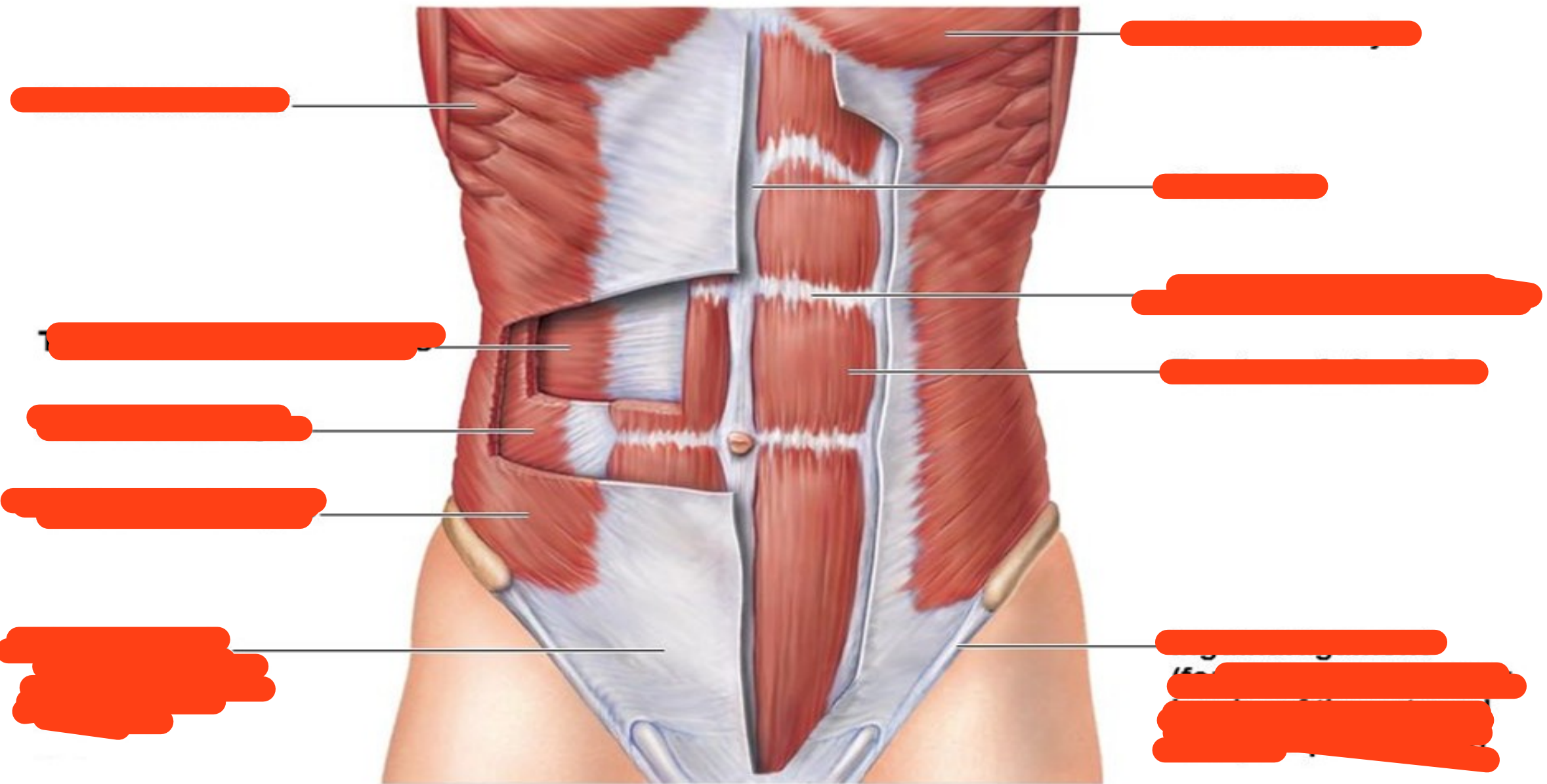
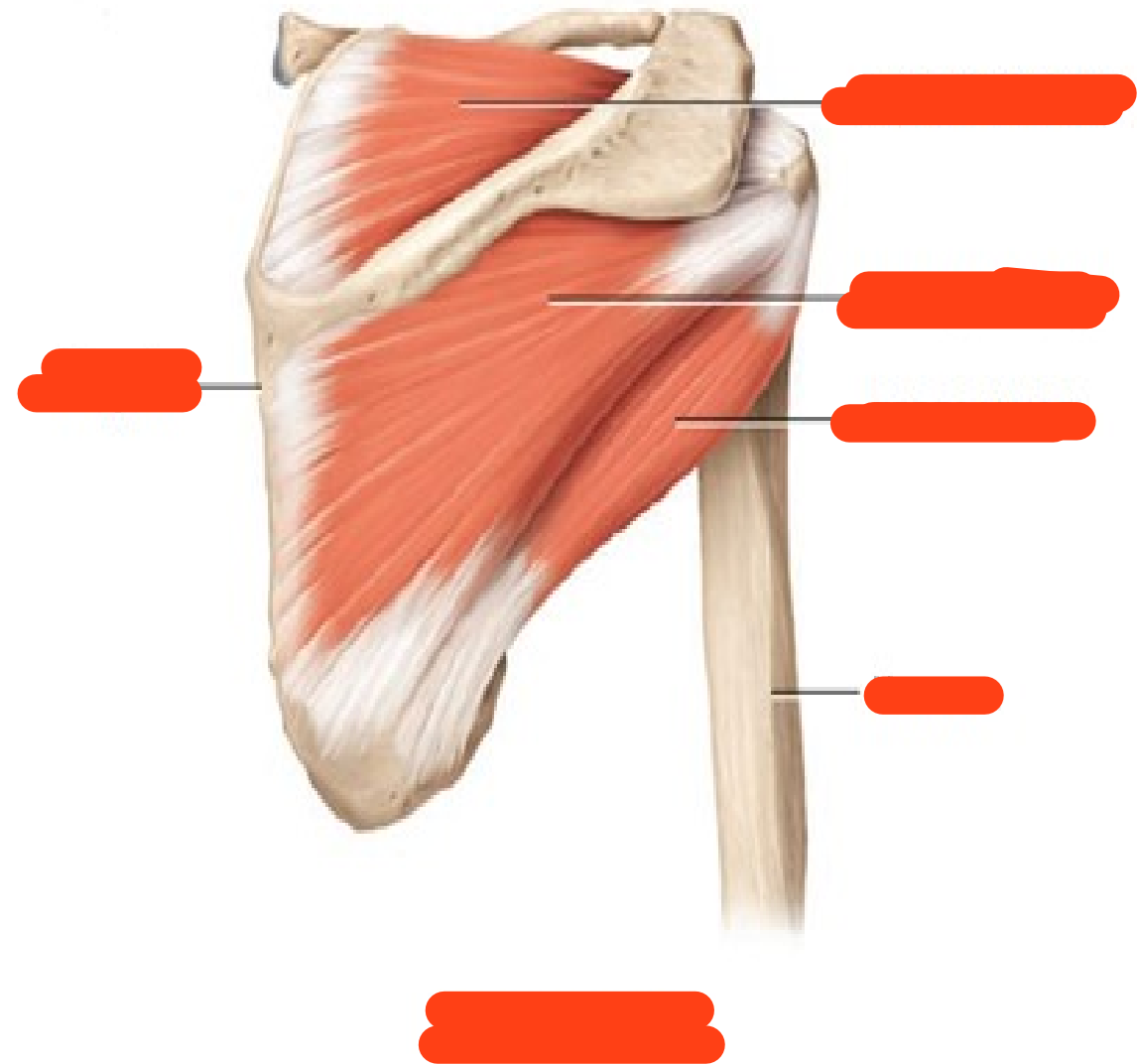
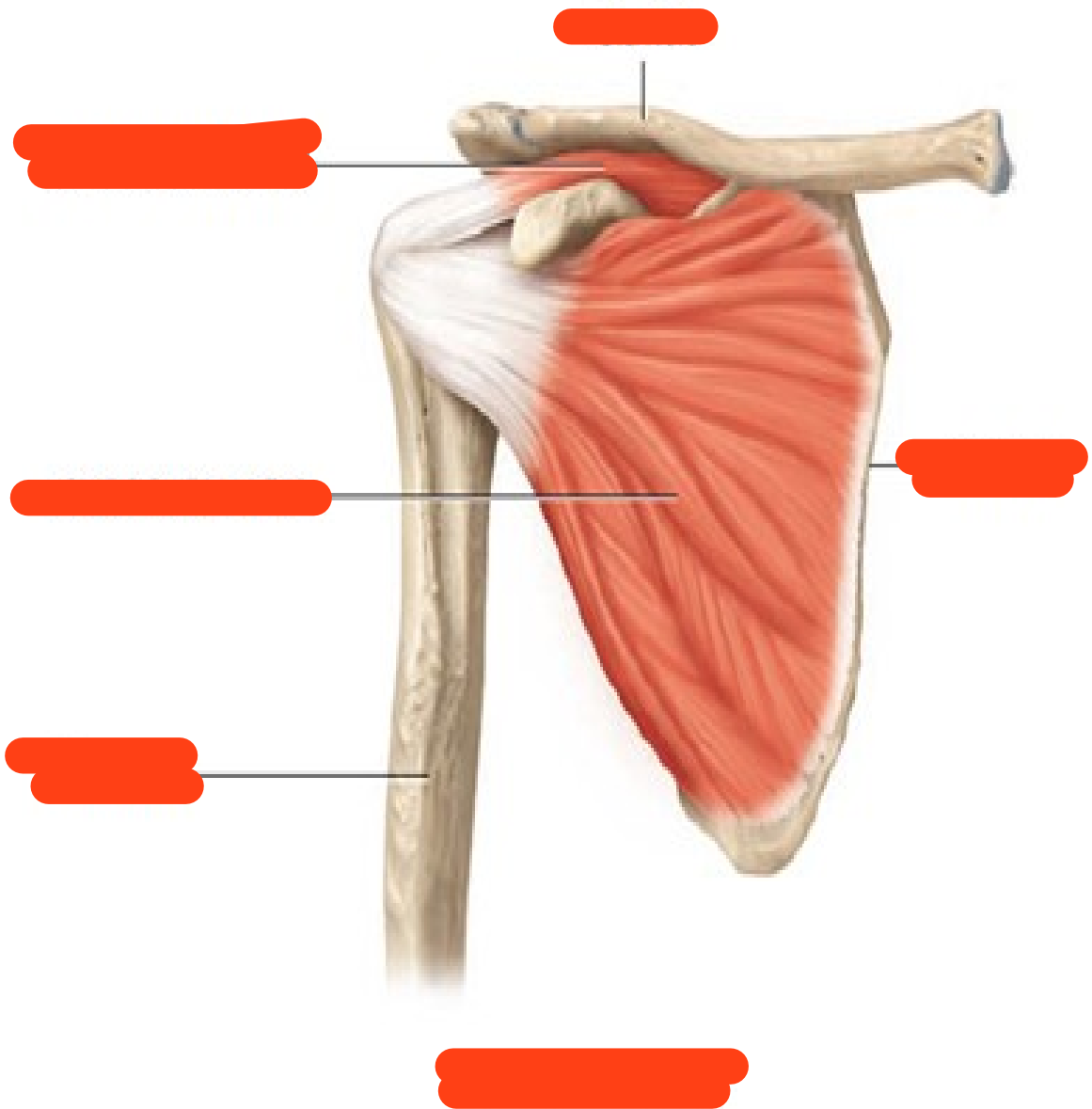
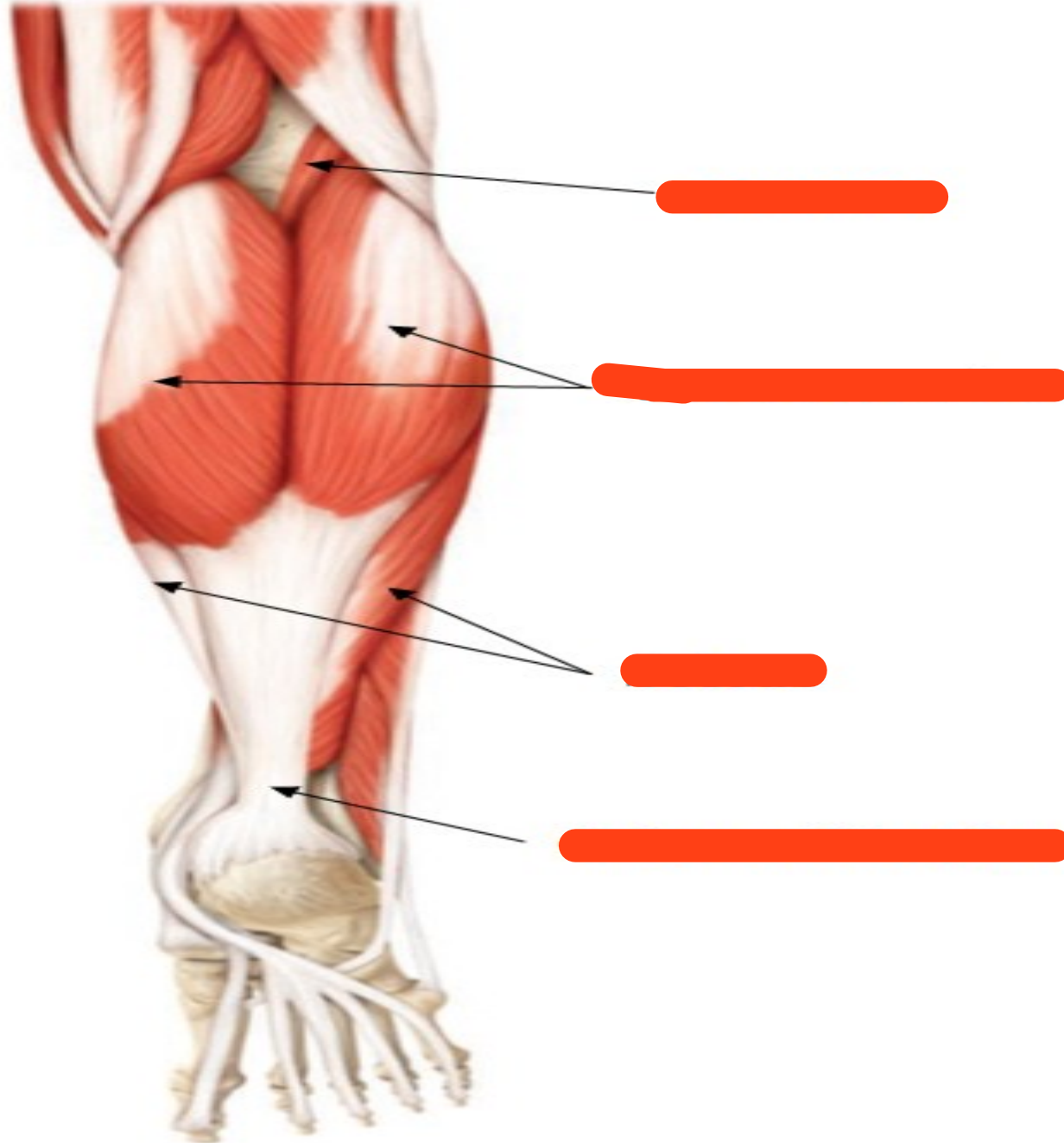
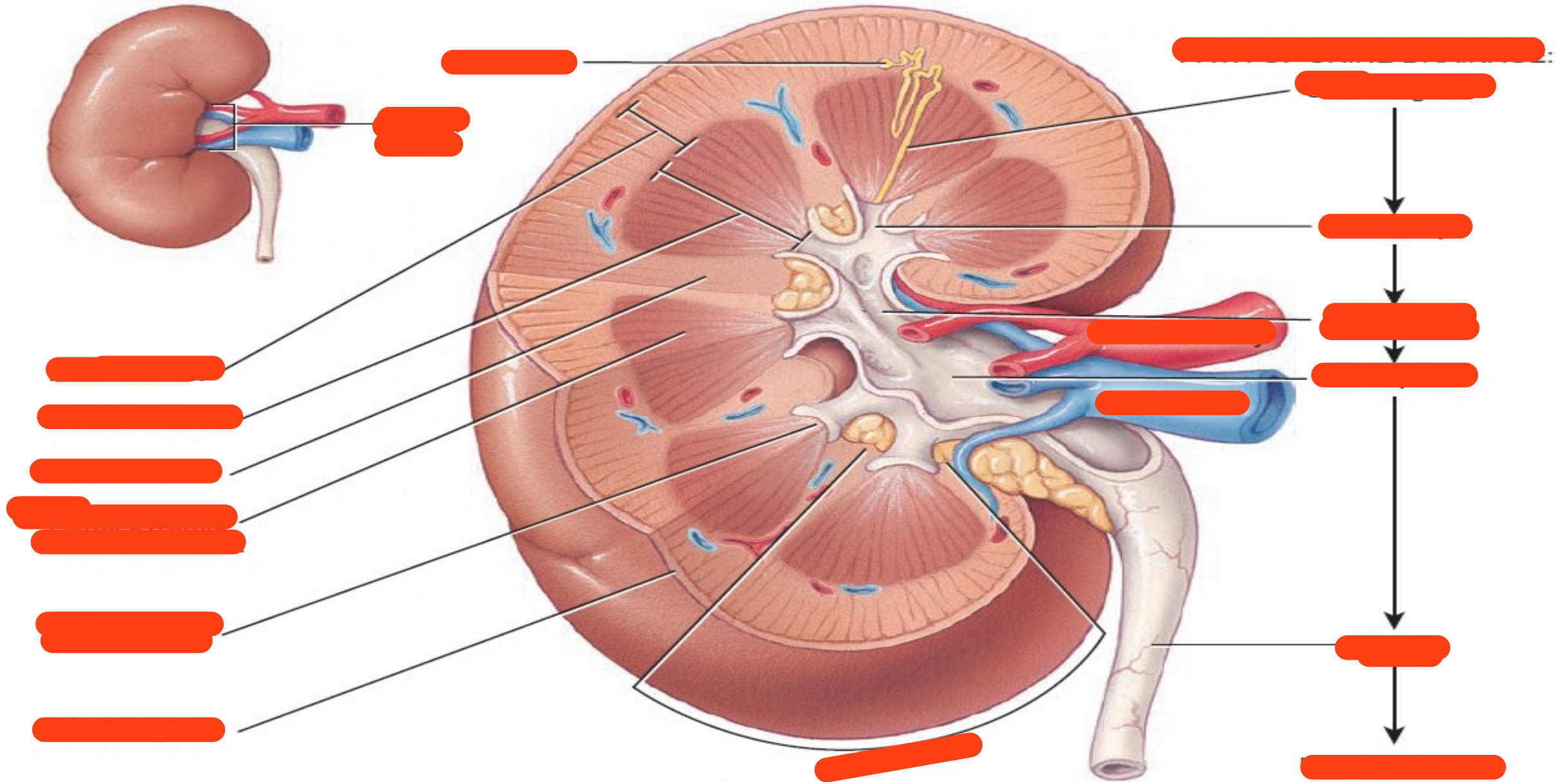


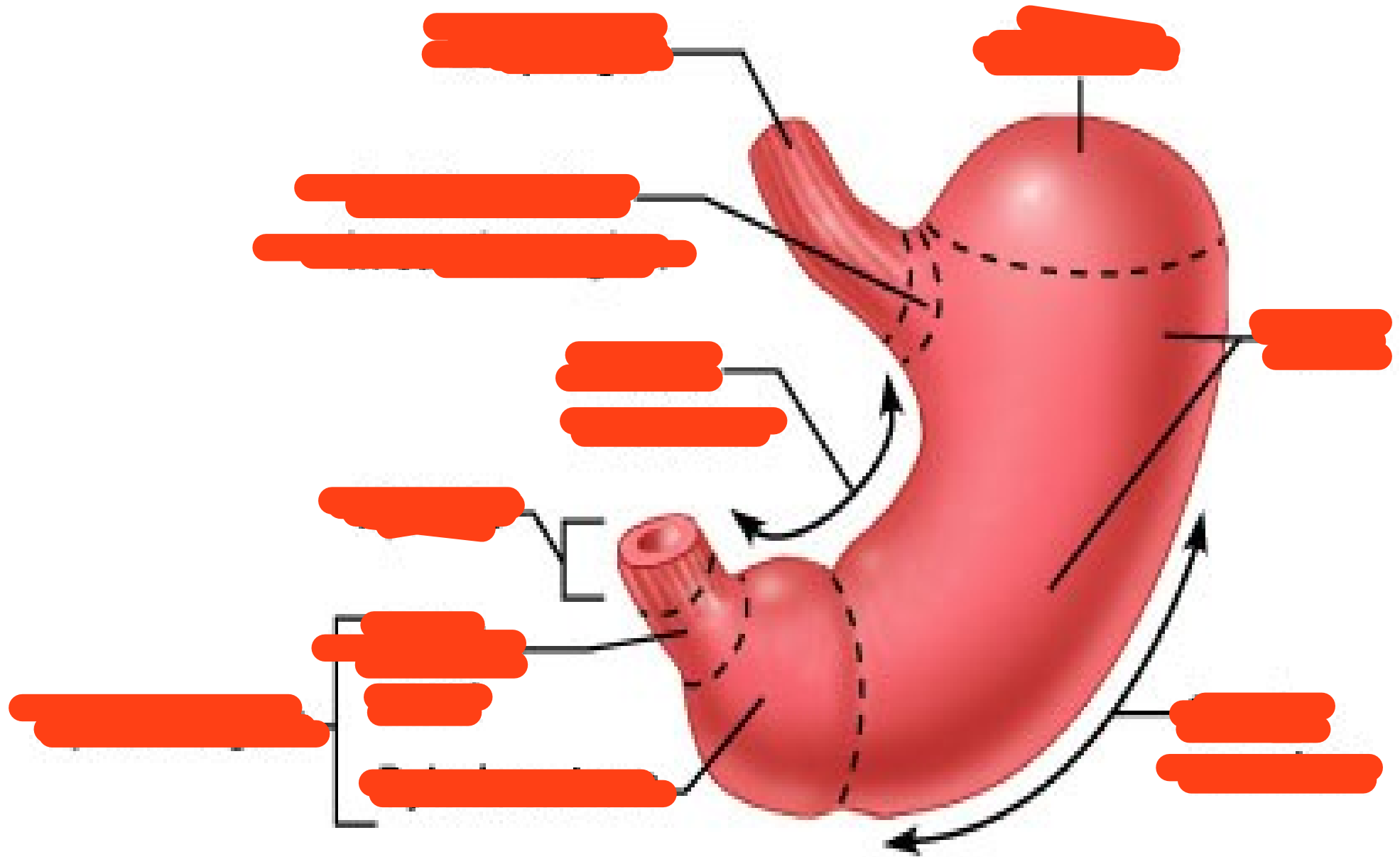
Fig.11: Boundaries of the triangles of the neck.

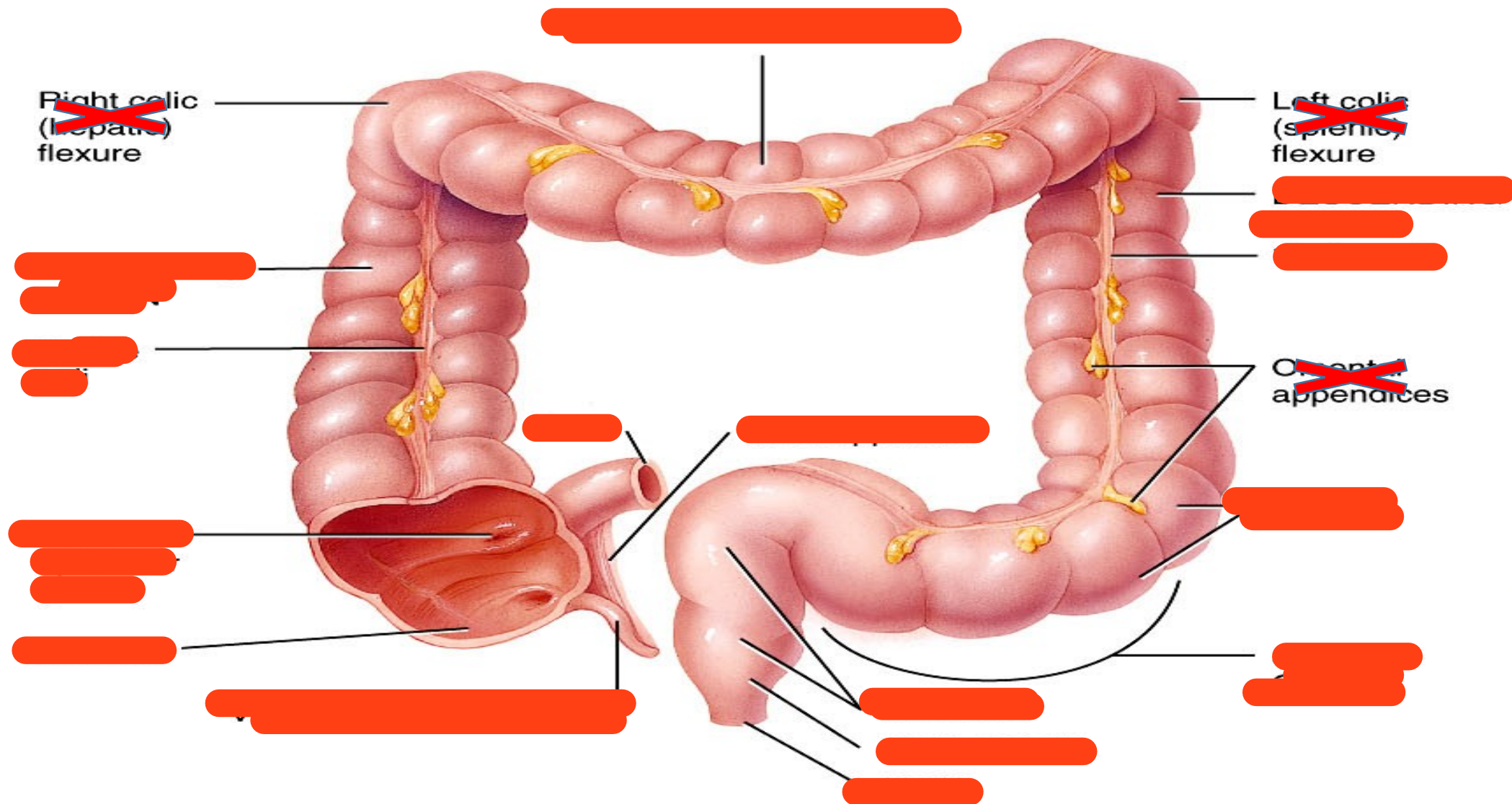


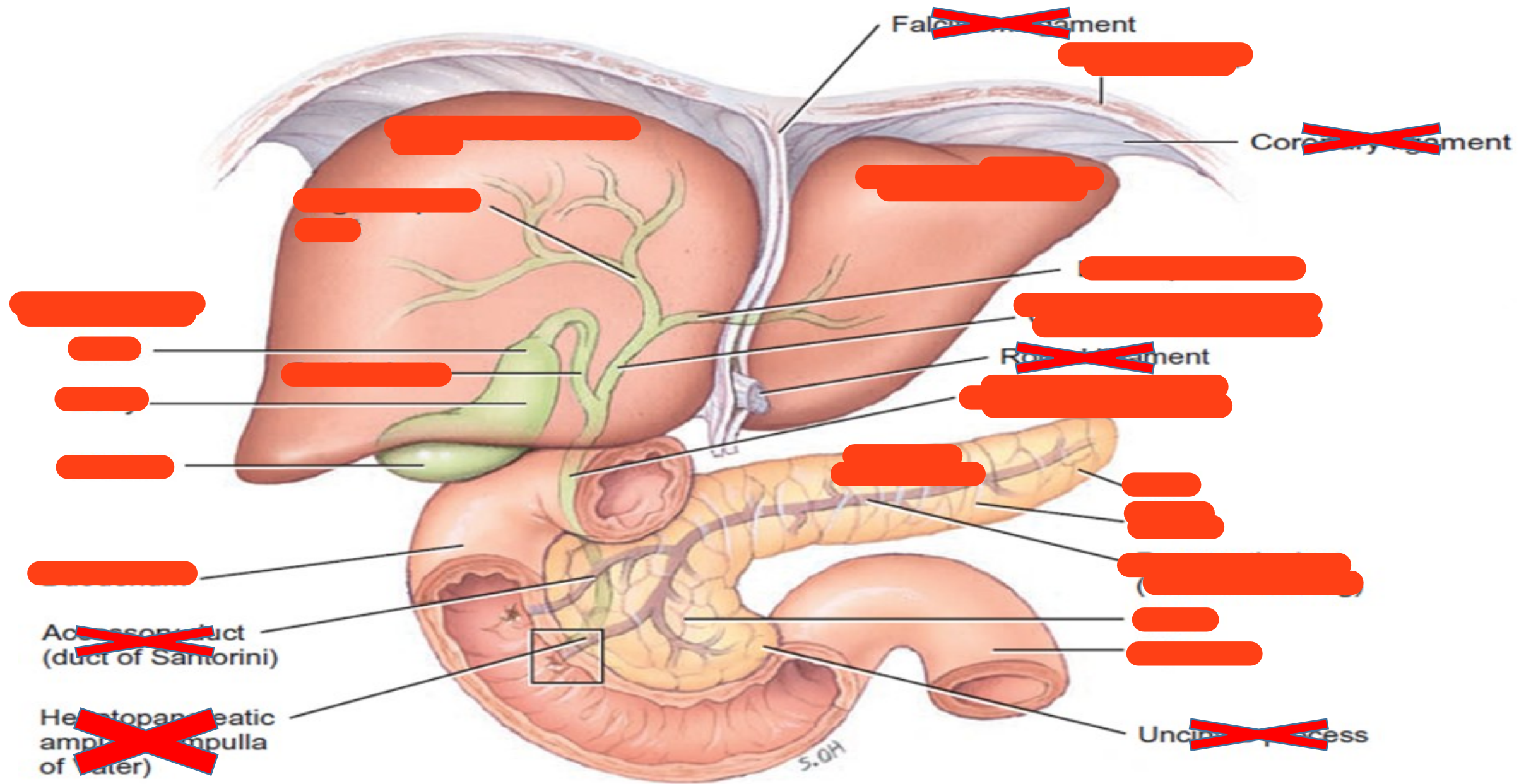


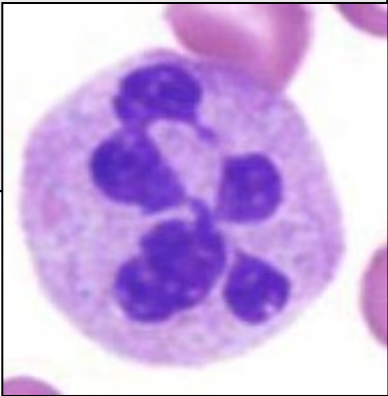
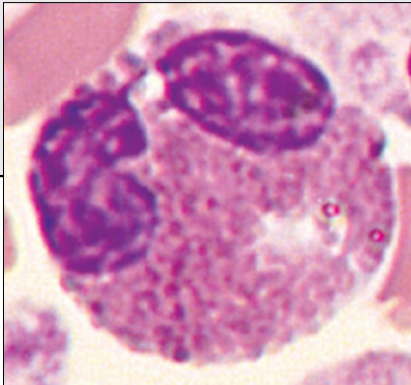
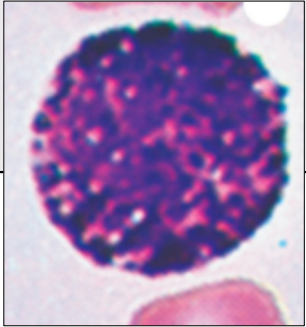




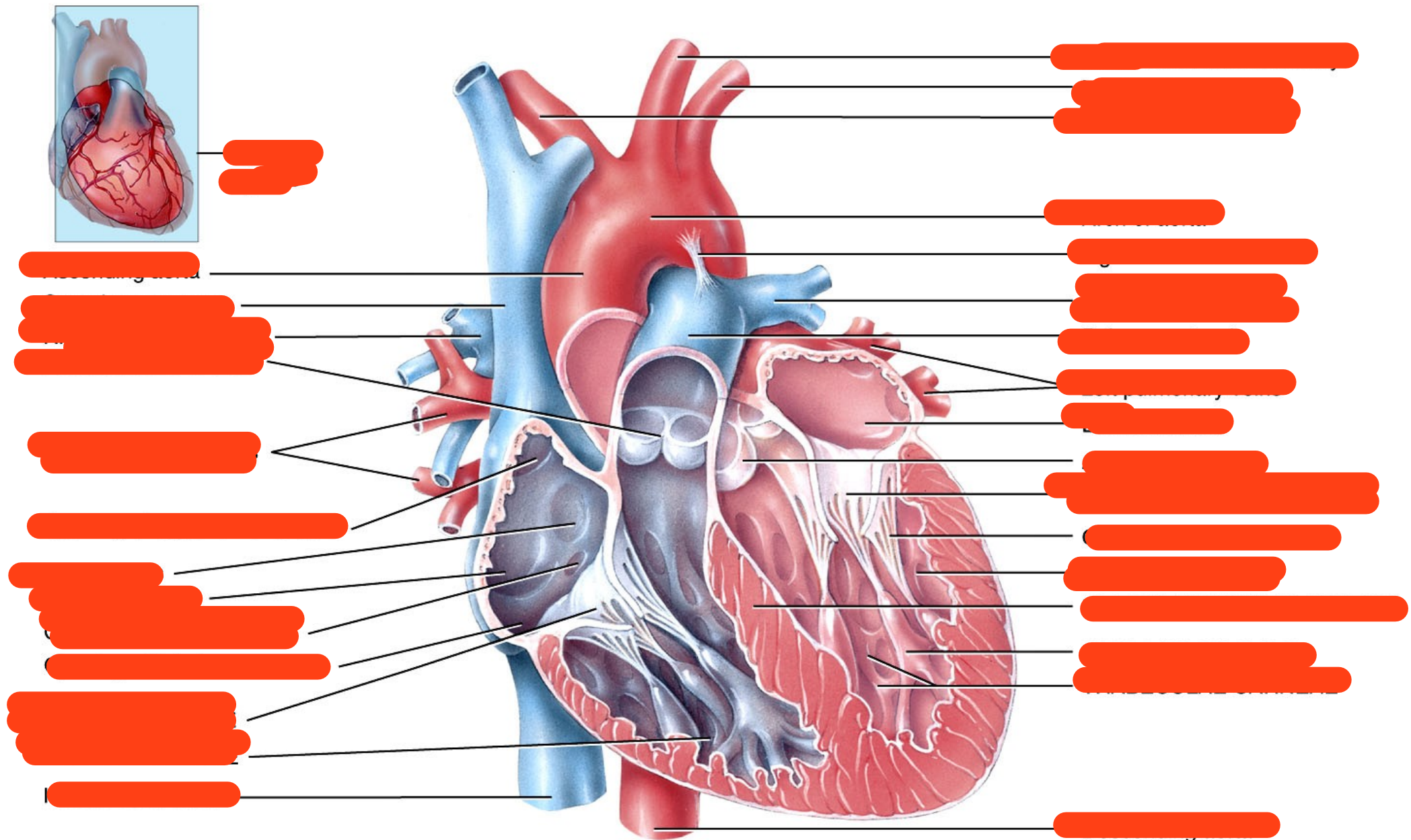




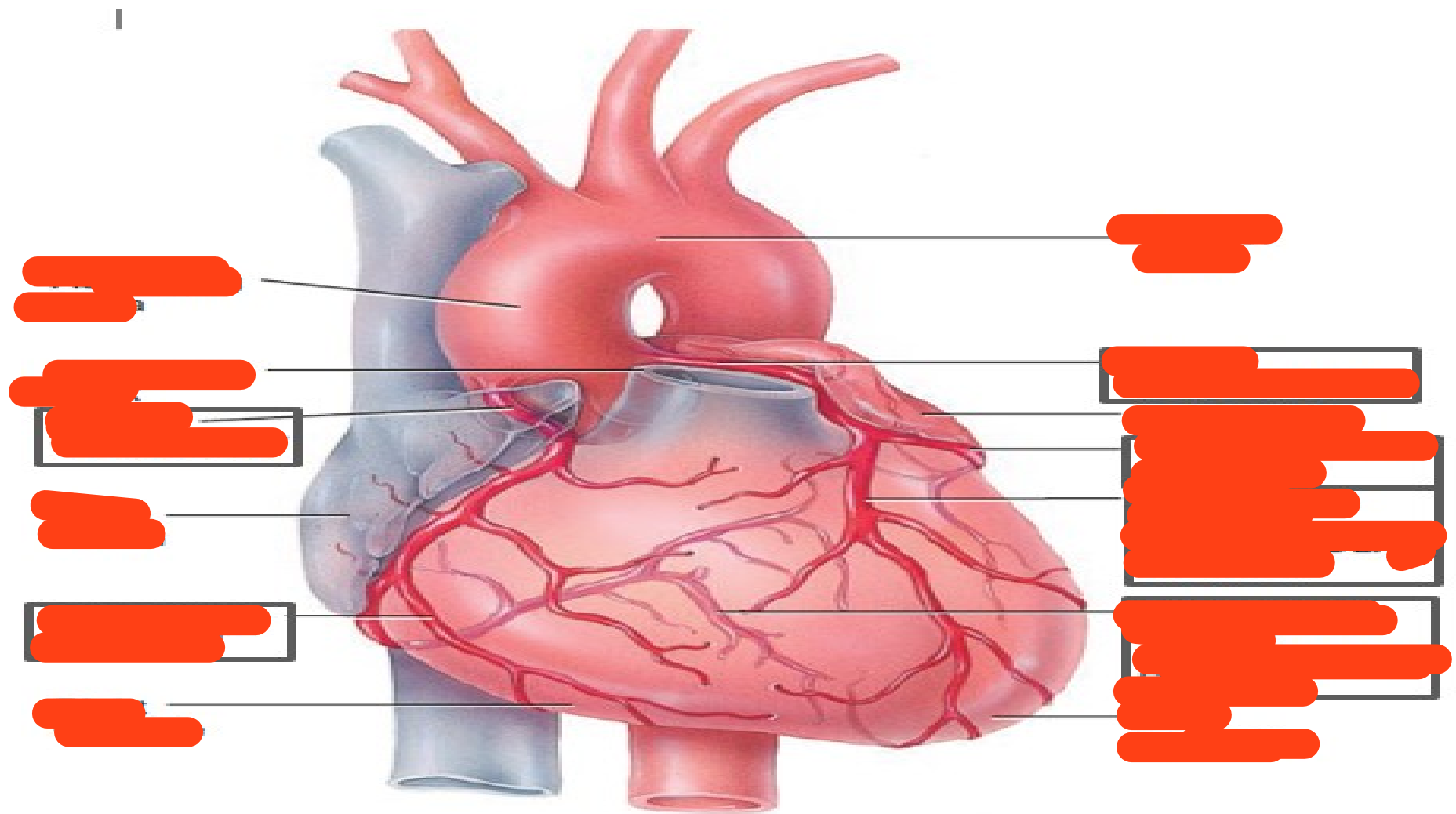


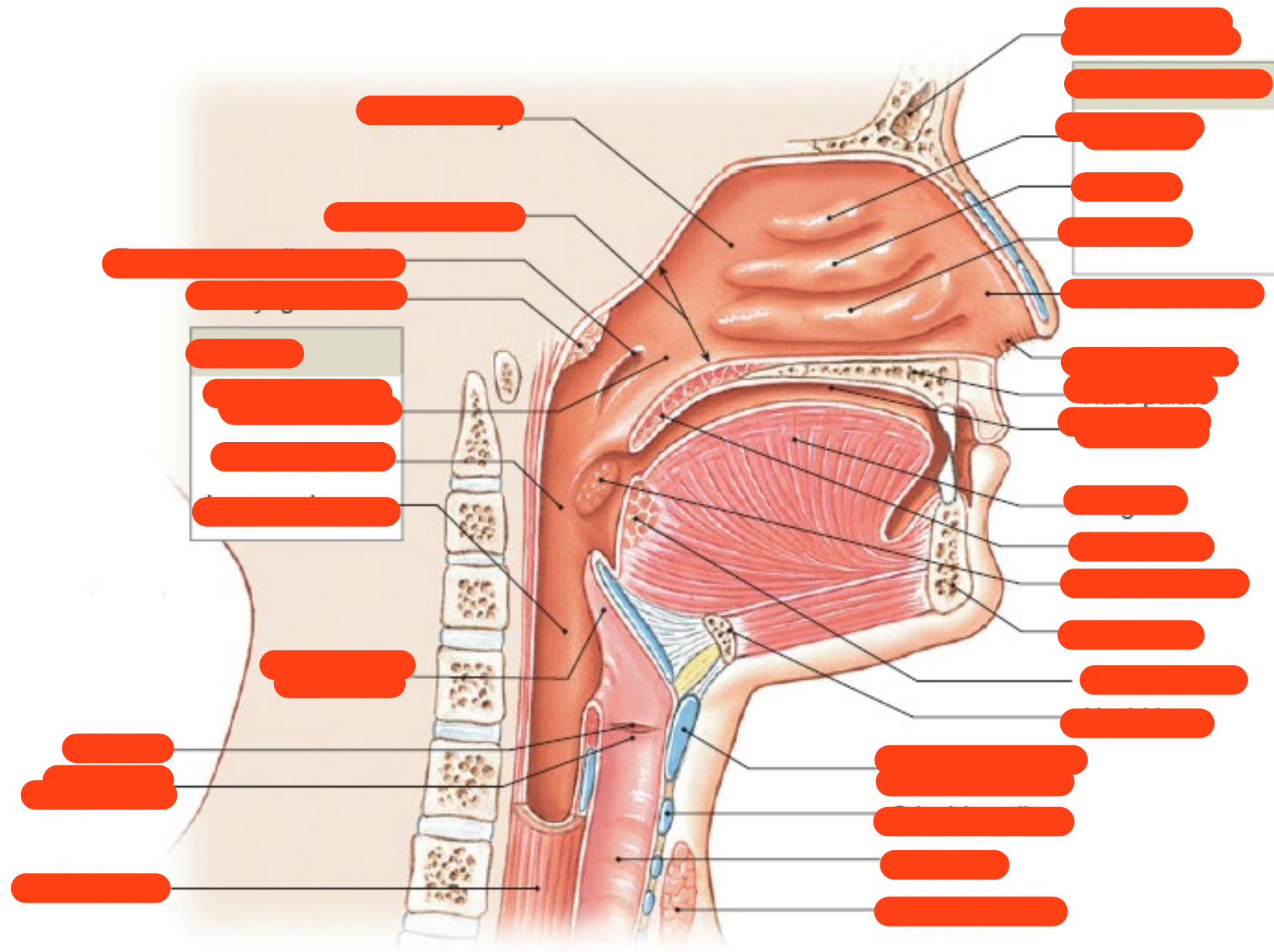
Granulocytes	Neutrophils	Eosinophils	Basophils
Abundance (% of leukocytes)	Most common		Least common
Nucleus	Multilobed	Bilobed	S shaped (obscured by granules)
Granules	Sparse and stain variably	Large eosinophilic	Large basophilic
Function	Phagocytosis	<ul style="list-style-type: none"> Defense against parasitic infection Allergic reactions 	Release of inflammatory molecules
Fig.4: Granulocytes.			





(a) Anterior view of frontal section showing internal anatomy





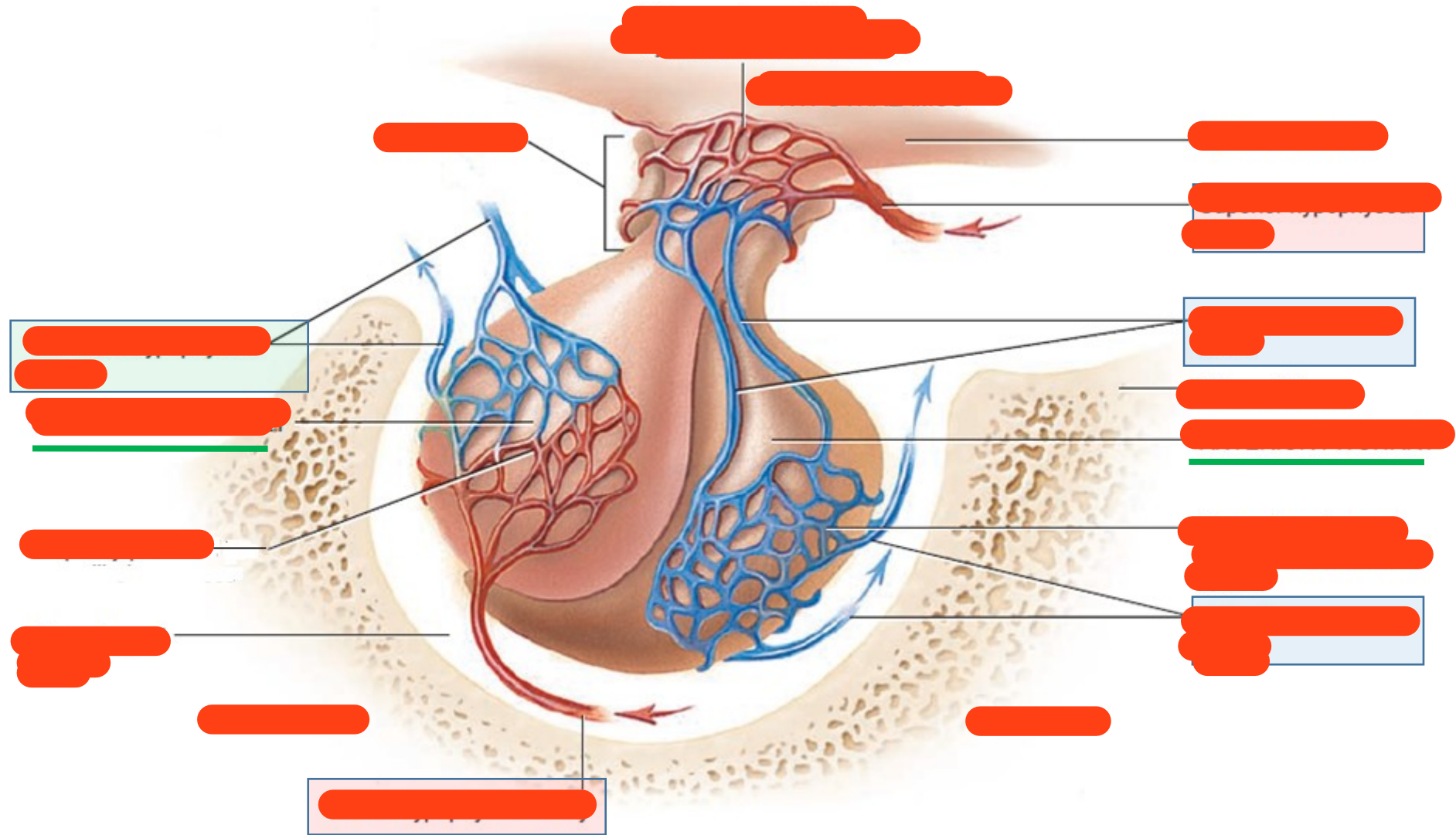


Fig.4: Blood supply of the pituitary gland.